The Australian and New Zealand Journal of Surgery

OCTOBER, 1943.

TABLE OF CONTENTS.

[The Whole of the Literary Matter in THE AUSTRALIAN AND NEW ZEALAND JOURNAL OF SURGERY is Copyright.]

ORIGINAL ARTICLES— PAGE

Some Remarks on the Surgery of Patent Ductus Arteriosus *P. W. Gebauer* 75

Air in the Cranial Cavity: A Critical Review, with Reference to an Unusual Case ..... *R. A. Money and A. Stoller* 82

Some Aspects of Royal Air Force Casualties ..... *E. T. Cato* 98
With Notes on the Bacteriology of War Wounds ..... *E. M. Darmady*

Orthoptics in the Field ..... *J. B. Hamilton* 107

The Use of Spinal Anæsthesia in General Surgical Practice .. *A. E. Brown* 111

SURGICAL TECHNIQUE—

The Introduction of the Intercostal Tube: An Improved Method *R. N. Howard* 119

CASE REPORTS—

Ganglioneuroma of the Suprarenal Gland .... *E. S. J. King* 123

Thymic Hyperplasia and Myasthenia Gravis ..... *E. S. J. King* 129

Horseshoe Kidney and Hydronephrosis ..... *R. Flynn* 138

SURGERY IN OTHER COUNTRIES—

War Injury of the Eye in Germany 140

REVIEWS—

Medical Ethics 140

The Hemorrhagic Diseases and the Physiology of Hemostasis 141

Plastic Surgery of the Breast and Abdominal Wall 141

Fractures and Fracture Treatment in Practice 142

Renal Lithiasis 142

Illustrations of Regional Anatomy 143

Intestinal Obstructions: A Physiological and Clinical Consideration 143

PROCEEDINGS OF THE ROYAL AUSTRALASIAN COLLEGE OF SURGEONS—

Admission of New Fellows 144

ROYAL COLLEGE OF SURGEONS OF ENGLAND—

Regulations for the Fellowship 144

Jacksonian Prize 144

Corrigendum.

In the issue of July, 1943, Major W. Lister Reid was described in the heading to his article on cerebral œdema as consulting neurosurgeon to an Australian general hospital. The title should have been visiting surgical officer.

Editorial Notices.

All articles submitted for publication in this journal must be typewritten and double or treble spacing should be used. Each article should conclude with a brief summary and statement of conclusions. Authors are requested to avoid the use of abbreviations and not to underline either words or phrases.

Authors are requested to submit two typescript copies of all articles.

References to articles and books should be carefully checked. In a reference the following information should be given without any abbreviation: initials of author, surname of author, full title of article, name of journal, volume, full date (month, day and year), number of the first page of the article. If a reference is made to an abstract of a paper, the name of the original journal, together with that of the journal in which the abstract has appeared, should be given, with full date in each instance.

When illustrations are required, good photographic prints on glossy gaslight paper should be submitted. Line drawings, charts, graphs and so forth should be drawn on thick white paper in indian ink. Authors who are not accustomed to prepare drawings of this kind, are invited to seek the advice of the Editor if they are in any doubt as to the correct procedure. Skiagrams can be reproduced satisfactorily only if good prints or negatives are available.

Editorial communications should be addressed to the Chairman of the Editorial Committee, 57 Collins Street, Melbourne, or to any member of the Editorial Committee. It is understood that original articles forwarded for publication are offered to The Australian and New Zealand Journal of Surgery solely, unless the contrary be stated.

Reprints can be supplied at cost price; the minimum number is fifty copies. Orders for reprints must be given when the proof is returned.

Exchange journals should be addressed to the Honorary Librarian, Royal Australasian College of Surgeons, Spring Street, Melbourne, C.1, Victoria, Australia.

Business communications and remittances should be addressed to Butterworth and Co. (Australia) Ltd., 6-8 O'Connell Street, Sydney.

The announcements appearing in this journal contribute largely towards the maintenance of the high standard of the publication. It is, therefore, requested that, wherever possible, readers will support the business houses whose advertisements appear in the journal and that, when placing their orders, they will mention The Australian and New Zealand Journal of Surgery.

THE AUSTRALIAN AND NEW ZEALAND JOURNAL OF SURGERY

Registered at the General Post Office, Melbourne, for transmission by post as a periodical.

VOL. XIII. OCTOBER, 1943. No. 2.

SOME REMARKS ON THE SURGERY OF PATENT DUCTUS ARTERIOSUS.[1]

By PAUL W. GEBAUER,
Major, Medical Corps, United States Army.

AFTER Munro's[1] prophetic paper in 1907, which suggested ligature of the patent *ductus arteriosis* in instances of threatened cardiac failure, and particularly after Strieder's[2] attempted ligation in 1938, the thought of ligating a patent ductus must have made many a surgeon's mouth water. Especially drooling were those who had performed dissection pulmonectomy on the left side and were, therefore, familiar with the living anatomy. This latter group, by the way, includes myself considerably more than not at all.

Following the first successful ligation by Gross,[3] the operation, after a fashion, conformed to the usual developmental stages of things new in surgery. The usual course of events begins with the first phase, a dramatic and acclaimed acceptance coinciding with a crescendo of successes published singly or in small series, and tapering off with a diminuendo of unpublished failures; this progresses to the second, the argumentative stage, in which opinions are freely expressed, but the material background is scanty and more often than not proof for profound statements is meagre. There follows the third, the longest period, where science noticeably raises her head, the period of investigation, solution and appraisal.

Such is the ordinary metamorphosis of things new in surgery. Perhaps the steps are less well defined, and perhaps they overlap somewhat in the procedure of ductus ligation because of the investigations and thorough work of Gross and his associates from the very beginning. So, in reality, the third phase already has been long in process. However, I do not believe that the entire solution and appraisal are complete. As I see it, we have come back to an old problem, the problem of ligating large arteries in continuity. To my knowledge, there is yet no method of ligation which insures complete and permanent closure in every case in which the ductus can be circumsected. Therefore, we are not ready to say that every patent ductus should be ligated, nor that the available statistical evidence indicates that in all cases the hazard of endarteritis is greater than the risk of operation.

My surgical experience has been limited to six instances of ligation and a number of explorations. Possibly it has been enriched somewhat by the protracted contemplation which intermittently pervades the mental idleness of one recently divorced from his calling. This diminutive experience makes

[1] Accepted for publication on March 1, 1943.

me feel that some of our problems are near solution, and that in time exploratory operations which prove the impossibility of ligature by surgical means, will be performed with increasing infrequency and also that in one group of patients ligation will always be performed.

The literature contains some excellent experimental work[4][5][6] concerning the mechanism of ductus closure; old theories have been revived and attractive new ones added, yet we are not completely outside the realm of theory, and we do not really know how the ductus normally closes nor why it sometimes remains open. Such knowledge might not be essential in the treatment of patency in later life, but it might be quite helpful.

Anatomical studies[6] of the newborn have shown the size, location, thickness and other characteristics of the ductus to be without much variation. This does not mean that every patient with a patency began life with a leak and a ductus of uniform size, but it may mean that the leak is the smallest and the ductus the longest in the beginning, as soon as the process of closure, whatever it is, fails to continue or take place. From here, I believe the process is one of gradual enlargement and shortening of the ductus, produced by dilatation of the pulmonary artery, as a result of its unnatural intralumenal pressure. In infancy, the aortic and pulmonary pressures might not be widely different, especially since the abnormal communication tends to equalize them. However, with body growth the demand of the systemic circuit increases proportionately more than that of the pulmonic circuit. How is this demand satisfied?

Eppinger and Burwell[7][8] believe the high percentage of cardiac output, which is shunted through the ductus and is thus lost to the systemic circuit, forces the left ventricle to achieve an output two or three times that of the right in the same period. This leads to a left ventricle hypertrophy which they usually found. On the other hand, Bettinger[9] suggests that the increased pulmonary pressure evokes an increase in pulmonary resistance by constriction of the small pulmonary vessels and right ventricular hypertrophy. By this means the pulmonary pressure approaches that of the aorta, thereby diminishing the amount of shunted blood, maintaining an adequate systemic circulation and preventing flooding of the pulmonary circuit.

It would be conjecture on my part to say that either of these theories was right or wrong. I regard it as important that they both implicate an abnormally high pulmonary pressure which, I believe, leads to the pathological changes that occasionally make safe ligature impossible. For the sake of argument, I can say that I favour the former theory for the following reasons. The physical finding in patent ductus is a continuous "machinery" murmur occurring where the ductus is closest to the chest surface, near the sternum at the second left costal cartilage or interspace, and radiating toward the left shoulder. There may or may not be a distinct thrill in the same area. The intensity of these signs is in direct relation to the volume and velocity of the blood following through the ductus and its nearness to the examining hand or instrument. At operation, when the pulmonary artery is not much enlarged, we find the ductus rather deep in the mediastinum, and a thrill may not be felt distinctly until the finger is placed there. In marked pulmonary dilatation the ductus is located just beneath the mediastinal pleura, seeming to bulge from the groove between the pulmonary artery and aortic arch, just a few centimetres from the anterior chest wall. The high intrapulmonary pressure is easily imagined when one palpates the artery. The thrill is much more intense on the pulmonary side. When the ductus is torn the blood gushes from the aorta.

In the older patients whom I have seen and who had a diminished cardiac reserve clinically and typical physical findings, a wide pulse pressure was

present which increased in response to severe exercise, as it does in cases of arterio-venous shunt, with a fall in diastolic pressure.

In a patient[10] on the verge of failure, in whom at operation the ductus separated from a calcified aortic wall, autopsy showed a generalized cardiac hypertrophy more marked in the left ventricle. In addition, a tremendous dilatation of the pulmonary artery and its branches was noted.

Pulmonary arteriograms taken with 70% "Diodrast" solution have shown dilated pulmonary arteries in the periphery of the lungs in those patients who had loud murmurs and intense thrills with mild cardiac symptoms.

Most of the typical radiological findings arise from an enlarged pulmonary artery and do not include a prominent right auricle. The presence of an enlarged right auricle in Bettinger's reported case, as well as the atypical murmur in the tricuspid area, the presence of cyanosis and the rather small pulse pressure, makes it differ from any case I have seen. Consequently, I quite naturally wonder if there could have been some other factor operating in the patient he reported. The above-mentioned factors, the larger right ventricle, and especially the paradoxical embolism, indicate that the leak was from pulmonary artery to aorta. Therefore, the mechanism was more than compensatory. Hypertrophy of the right ventricle and constriction of the medium and small lung arteries did not just keep the shunt at a minimum by tending to approximate the pressures in the aorta and the pulmonary artery. They did more than that. They raised the pulmonary pressure above the systemic, so that the ductal flow was reversed, and embolism from a renal vein to a splenic artery occurred shortly before death from circulatory failure. I hesitate to accept this as the usual dynamic state in uncomplicated patent *ductus arteriosus* and I wonder if the pulmonary vessel sclerosis may not have been a significant factor in this unusual case, or if the enlarged liver and pronounced venous congestion may not have resulted from a relative tricuspid insufficiency.

The above theoretical discussion is not entirely beside the point, for we should have some understanding of what we are trying to correct and avoid when we contemplate ligature of a patent ductus. I believe the available evidence dictates the inclusion of this anomaly in the category of arterio-venous shunts. As Bettinger pointed out, whether the mechanism of compensation is as he or as Eppinger and Burwell postulate, there is no doubt that the leak should be closed.

On the other hand, regardless of the mechanism, the compensation is frequently so adequate that many of these patients appear to live perfectly normal, active lives, and partake in strenuous athletics during childhood and adolescence, despite caution to the contrary. Some seem to be comfortable even in late years. These clinical experiences, in some ways, contradict the pathological statistics[11][12] so far collected. When we see a child, apparently in perfect health, with a typical thrill and murmur, it may seem unlikely that the average age at the time of death would be twenty-four years in a group of such children, or that 30% or more would contract bacterial endarteritis, or that the cause of death in 80% of cases would be cardiac failure. The doctors who have followed the apparently good health of some of these patients for years are especially reluctant to consider such figures seriously.[13] Just as impressive, however, is the clinical experience of three cardiac tragedies in such individuals in a single family.[13] Furthermore, when we remember that endarteritis may occur at the age of sixty-three,[14] we know that in a given patient its possibility threatens so long as he lives. Naturally, such conflicting experiences produce a certain amount of discord and raise the following questions. What patients should be operated on, and what patients should not? What is the risk of operation, and what is the

prognosis without it? Some men believe the operation should be done only when the myocardium begins to fail or infection has occurred, and that prophylactic operation is not justified. Others believe that the prophylactic operation should be done, and still others that operation should be performed in all cases.

Our decision should be governed by the available methods at hand and the degree of hazard which attends their use. As previously stated, there is no certain method of complete closure in all cases. The problem of safe ligation of large, short, thin-walled and sometimes sclerotic ducti is not yet solved. To my mind, the feasibility and the safety and the likelihood of complete and permanent closure depend, for the most part, on the degree of pathological change resulting from the open shunt. This change is essentially dilatation of the pulmonary artery and its branches, which may vary somewhat in the beginning when one case is compared with another. The degree of this change is the key to our surgical problems, and I believe it is a consequence of the duration of the leak more than the other contributing factors, such as the original size of the ductus, the myocardial and vascular bed response to the altered dynamics, the circulatory rate and the activity of the patient.

Despite its thin walls and its failure to thicken appreciably, the pulmonary artery enlarges relatively slowly. The ductus shortens and widens as it takes part in this process, much as the fingers of a rubber glove shorten and distend when the whole glove is inflated. Its original position, rather deep in the mediastinum, gradually shifts forward and laterally as the pulmonary artery bulges toward the anterior chest wall. The degree of dilatation in the presence of the transmitted aortic pressure is sometimes tremendous.

I have seen an artery twice the diameter of the aorta and approaching transparency because of its distended state. Touroff[14] reports one which overlapped the aortic arch. Such instances of advanced change are seen in the older patients. Occasionally the ductus practically becomes a part of the pulmonary arterial wall, and exists only to mark the site of an open communication between two adjacent vessel walls. An attempt to dissect out such a structure has proved to be too hazardous more than once.

Johnson *et alii*[16] and Touroff[15] have reported methods of dissection designed to avoid injury to the ductus—a strong indication in itself of the dangers encountered. A circumsection just removed from the thin ductal wall is difficult and entails trauma to neighbouring structures, such as the pulmonary artery, aorta, recurrent laryngeal nerve and the pericardium. We know that injury to the adventitia of an artery produces degenerative changes in the media which, in time, may contribute to rupture or aneurysm formation. The dissection is most difficult and dangerous posteriorly between the ductus and the left main branches. Here the tissue is rather dense and fibrous because it is one of the sites of origin of the pericardium.

In cases of successful dissection in the presence of marked pathological changes, there is always the possibility of a tear or subsequent erosion when ligature is attempted, because of sclerosis at the ductal orifices.

Some doctors would have the surgeon treat only this group of patients, the one to which, I feel, surgery has the least to offer. These patients are usually middle-aged or older, have evidence of myocardial failure, and have escaped endarteritis. X-ray examination reveals a huge pulmonary artery and calcification at the site of the ductus may be seen. Exploratory operation is likely to be useless and perhaps fatal.

There is a second group of patients, usually ranging from the age of fourteen to the late twenties, who have led active lives and whose heart disease previously has been little more than something to which the doctor

listens. The common complaints are increased heart consciousness, palpitation, dyspnœa with exertion and fatigue. Frequently the onset of such symptoms is rather sudden; it may be insidious. In this group the heart is just beginning to reach for the last of its reserve and the pathological changes are ordinarily fairly well advanced. The pulmonary artery at operation is distinctly larger than the aorta. The ductus is just beneath the mediastinal pleura, and at first it appears to have no appreciable length. Careful dissection will reveal it be five to eight millimetres long and about as wide. Its wall is thin. Sometimes there is room for only one ligature. More often than not when two are passed, they are side by side before the operation is completed. If the ligature is tight enough to produce intimal approximation and permanent healing, there is some risk of immediate hæmorrhage, and late hæmorrhage by erosion or false aneurysm formation is an unfortunate possibility. If the ligature is tied loose enough to prevent vessel wall injury, the functional result may be good, but the murmur continues or recurs and the leak continues. The hazard of infection is still present, if not actually enhanced. Because of these possibilities I believe that simple ligature is unjustified in some of these patients and that the risk of ligation is just as great as the hazard of endarteritis in the future.

The problem in the above group boils down to the difficulty in completely and safely ligating large arteries in continuity. The procedure found successful in Owings's[17] experiments is, of course, not applicable here, for the site of closure is unchangeable. However, a staged procedure at the same site is not without the realm of possibility. A method more likely to prove a solution is that suggested by Pearse,[18] who was able to occlude the thoracic aorta of dogs by means of the inflammatory and fibrotic reaction to "Cellophane". Gross has repeatedly used this in cases of patent *ductus arteriosus*. The ductus is ligated to the point of obliteration of the thrill. Complete and permanent closure is accomplished by wrapping the ligated ductus with a strip of "Cellophane" which sets up an intense fibrotic and inflammatory reaction, designed to complete the operation in ensuing weeks by fibrotic contracture and replacement. I know that Gross has had success with this method. I do not know if he has had any failures. I did. An eighteen-year-old patient who, despite a good functional result, continued to have a murmur, months later died after the development of a huge false aneurysm and endarteritis.[1] In another, aged nineteen years, the murmur had persisted for a period longer than the time in which closure by fibrosis would ordinarily be expected. Some method of closure by stimulating cellular reaction following an initial ligature, nevertheless, seems to hold promise. Possibly our problem in this group is near solution.

In the third group of patients the ductus can be ligated completely, safely and permanently, and the operation should be regarded as a prophylactic measure. The patients are usually older than three years and rarely more than twelve or fourteen. They have no symptoms, but have been guided into a *régime* of restricted activity because of congenital heart disease. A thrill might not be palpable, but usually is, and fluoroscopy or radiographic examination may or may not reveal a prominent pulmonary artery. The blood pressure is within the normal range, but an increase in pulse pressure can almost always be elicited following severe exercise.

At operation a thrill is always present. The ductus is found more nearly at its original position within the mediastinum, and is located by palpation of the thrill and noting its intensity. The vagus and recurrent laryngeal nerves are dissected free, and the ductus is carefully dissected from

[1] The author has been informed that all signs and symptoms in this patient disappeared between the second and fifth post-operative months.

the surrounding structures. As a rule it is found to be a fairly long structure, with a diameter that seldom exceeds four to six millimetres. It can be ligated safely and completely with separate ligatures, and sometimes it can be divided. The operation is straightforward, simple and without more risk than any major operation and anæsthetic. Invariably it should result in complete and permanent closure, without the dangers of hæmorrhage, aneurysm formation, or of an outpocketing of the vessel wall which might conceivably favour endarteritis.

At the present stage of our surgical means, the last-mentioned group is the one for which the operation has the most to offer. Once a patent ductus has persisted for three years or more, with enough of a leak to permit a good clinical diagnosis, I feel that spontaneous closure will never occur. I know of no proven instance of closure. I believe a process of pulmonary artery and ductal dilatation gradually progresses until surgical closure becomes difficult and finally impossible with our present methods. In this group of young patients I consider a successful operative result almost a certainty, and the risk of operation slight compared with the hazard of infection or cardiac failure, even if future statistics should prove the incidence of infection to be only 10% and cardiac failure 20%.

A fourth type of patient one might see, is one with a patent ductus complicated by bacterial endarteritis. This infection does not alter the surgical problems mentioned above particularly, except that it may produce a weak area in a portion of the vascular structure, thereby increasing the hazard of hæmorrhage or other complications. The presence of this infection and the knowledge of reported surgical cures with and without chemotherapy[14][15][19] justify attempted ligature in the face of advanced pathological changes evident from clinical study. Inasmuch as the chances of cure by ligature are better early in the disease, an initial *régime* of chemotherapy should not be prolonged if clinical improvement is not remarkable, unless the degree of pathological change is so advanced that a successful operation is a most remote possibility at best. In such instances chemotherapy alone seems justified in the hope of adding another non-surgical cure to the two already reported.

The remaining group of patients consists of those in whom other abnormalities of the heart and great vessels accompany a patent ductus. In general, ligation is indicated when there is a good probability of success and the ductus is known not to be performing a compensatory function—something which is much more easily stated than determined.

REFERENCES.

[1] J. C. Munro: "Ligation of the Ductus Arteriosus", *Annals of Surgery*, Volume xlvi, 1907, page 335.

[2] A. Graybiel, J. W. Strieder and N. H. Boyer: "An Attempt to Obliterate the Patent Ductus Arteriosus in a Patient with Subacute Bacterial Endarteritis", *American Heart Journal*, Volume xv, 1938, page 621.

[3] R. E. Gross and J. P. Hubbard: "Surgical Ligation of a Patent Ductus Arteriosus: Report of First Successful Case", *The Journal of the American Medical Association*, Volume cxii, 1939, page 729.

[4] J. A. Kennedy and S. L. Clark: "Observations on Ductus Arteriosus of the Guinea Pig in Relation to its Method of Closure", *Anatomical Record*, March, 1941, Volume lxxix, page 349.

[5] J. A. Kennedy and S. L. Clark: "Physiological Reactions of the Ductus Arteriosus", *American Journal of Physiology*, March, 1942, Volume cxxxvi, page 140.

[6] G. J. Noback and L. Rehman: "The Ductus Arteriosus in the Human Fetus and Newborn Infant", *Anatomical Record*, December, 1941, Volume lxxxi, page 505.

[7] E. C. Eppinger and C. S. Burwell: "The Mechanical Effects of Patent Ductus Arteriosus on the Heart", *The Journal of the American Medical Association*, Volume cxv, 1940, page 1262.

(8) E. C. Eppinger, C. S. Burwell and R. E. Gross: "The Effects of the Patent Ductus Arteriosus on the Circulation", *Journal of Clinical Investigation*, March, 1941, Volume xx, page 127.

(9) H. F. Bettinger: "Patency of the Ductus Arteriosus in Adults", *The Medical Journal of Australia*, Volume ii, 1941, page 418.

(10) P. W. Gebauer and A. D. Nichol: "Ligation of Patent Ductus Arteriosus", *Ohio State Medical Journal*, June, 1941, Volume xxxvii, page 538.

(11) M. E. Abbott: "Atlas of Congenital Cardiac Disease", 1936.

(12) J. C. Jones, F. S. Dolley and L. T. Bullock: "Diagnosis and Surgical Therapy of Patent Ductus Arteriosus", *Journal of Thoracic Surgery*, April, 1940, Volume ix, page 413.

(13) Discussion on references (3) and (7), *The Journal of the American Medical Association*, Volume cxv, 1940, page 1264.

(14) A. S. W. Touroff and H. Vesell: "Experiences in the Surgical Treatment of Subacute Streptococcus Viridans Endarteritis Complicating Patent Ductus Arteriosus", *Journal of Thoracic Surgery*, October, 1940, Volume x, page 59.

(15) A. S. W. Touroff, H. Vesell and J. Chasnoff: "Operative Cure of Subacute Streptococcus Viridans Endarteritis Superimposed on Patent Ductus Arteriosus: Report of the Second Successful Case", *The Journal of the American Medical Association*, Volume cxviii, 1942, page 890.

(16) J. Johnson, W. A. Jeffers and A. Margolies: "Technique of Ligation of Patent Ductus Arteriosus", *Journal of Thoracic Surgery*, February, 1942, Volume xi, page 347.

(17) J. C. Owings and J. E. Hewitt: "Successful Experimental Ligation and Division of the Thoracic Aorta", *Annals of Surgery*, April, 1942, Volume cxv, page 596.

(18) H. E. Pearse: "Experimental Studies on the Gradual Occlusion of Large Arteries", *Annals of Surgery*, November, 1940, Volume cxii, page 923.

(19) A. S. W. Touroff: "Further Experiences in the Surgical Treatment of Subacute Streptococcus Viridans Endarteritis Superimposed on Patent Ductus Arteriosus", *Journal of Thoracic Surgery*, October, 1942, Volume xii, page 1.

AIR IN THE CRANIAL CAVITY: A CRITICAL REVIEW, WITH REFERENCE TO AN UNUSUAL CASE.[1]

By R. A. Money,
Colonel, Australian Army Medical Corps,

AND

A. Stoller,
Major, Australian Army Medical Corps.

(From a Neurosurgical Centre at an Australian General Hospital in the Middle East.)

Fracture or erosion of the cranial air sinuses allows air to pass into the neighbouring tissues. The air may pass extracranially into the tissues of the scalp, when the condition is referred to as extracranial pneumatocele (aerocele), or the air may enter the cranial cavity, when the condition is referred to as pneumocephalus (intracranial pneumatocele or aerocele).

Extracranial pneumatocele is a relatively minor disorder, and the air remains in the subaponeurotic layer of the scalp or tissues of the orbit. This air may be made to disappear or move about by pressure on the "tumour", but the space may subsequently refill with air which has been forced out by swallowing, coughing or sneezing. The air may be in the frontal region (from the frontal sinus) or in the occipital region (from the mastoid air cells).

Pneumocephalus is not so rare as the literature would indicate. Thus Coleman,[33] in a review of 940 cases of trauma to the head seen during 1935 and 1936, reported four cases, an incidence of nearly 0·5%. Dean Lewis[31] stated that up to 1932 40 cases of pneumocephalus had been reported in the literature, though he considered the incidence of the condition much more frequent than this. The first description of pneumocephalus was given by Chiari[1] in 1884, while its first recognition by radiology was made by Luckett[2] in 1913.

The terminology of these conditions is somewhat confusing, as can be seen from the titles of the bibliography available, but that followed here is from Dean Lewis.[31]

Pathology.

Sufficient reference has already been made to extracranial pneumatocele, and only the pathology of air within the cranial cavity will be discussed.

In the early stages after trauma to the anterior part of the skull, free bleeding may occur from the nose and the tissues surrounding the frontal sinus may be bruised and œdematous. Regarding the bony damage, there may be fracture of the frontal sinus with depression of both inner and outer walls; the cribriform plate of the ethmoid may be involved, as also may the walls of the orbit; and the fracture may pass through to the optic canal and cause damage to the optic nerve.

The initial trauma or erosion may be followed by the immediate passage of cerebro-spinal fluid externally through the nose (rhinorrhœa) or this may be delayed. Infection may pass up through this track from the nose into the cranial cavity and cause a meningitis which is most often pneumococcal.

[1] Accepted for publication on February 9, 1943.

The phenomenon of rhinorrhœa is thus intimately bound up with pneumocephalus and may result, as Cairns[32] has stated, from:

1. Trauma (including operative procedures), when it may be: (*a*) immediate, (*b*) delayed.
2. Erosion of bone due to: (*a*) chronic infections, mainly tuberculosis or syphilis; (*b*) neoplasms. In these cases it is usually spontaneous, though it may be finally precipitated by trauma.

The rhinorrhœa may be a clear watery discharge of cerebro-spinal fluid indicating its origin from the subarachnoid space or a ventricle. If the discharge is sero-sanguineous or yellowish in colour, it indicates an origin from a walled-off cavity involving the frontal lobe of the brain.

The initial trauma may also allow an immediate passage of air into the cranial cavity, either into the subdural or the subarachnoid spaces, or, further, into the brain itself. The occurrence of extradural pneumocephalus has not been encountered, and it is considered extremely unlikely that air could enter the cranial cavity under sufficient pressure to strip the *dura mater* from the skull unless this had been already done by arterial hæmorrhage or at operation. Thus when air is found within the cranial cavity, both bone and dura must have been damaged. The *dura mater* is thinner and more adherent over the bones of the paranasal sinuses than elsewhere; hence dural tears and erosions are commoner in lesions of these regions. In two of the four cases seen by Coleman,[33] air was present within the subarachnoid space, while in two, pockets of air appeared to be present in the frontal lobes of the cerebral hemispheres. In one of the former cases there was also a small amount of air in a lateral ventricle. In a case reported recently by G. Phillips, of Sydney (reference unavailable), a large and variable collection of air was present in the subdural space.

If the air remains sterile, it may be absorbed rapidly and spontaneous recovery may occur in a few days, or it may persist for weeks or months without infection. Once the portal of entry is closed, however, the air is as a rule rapidly absorbed and replaced by cerebro-spinal fluid as in encephalography and similar procedures. If infection with the bacterial flora of the nose or sinuses takes place, then meningitis occurs with the production of purulent fluid within the subdural space (pachymeningitis) or turbid cerebro-spinal fluid in the subarachnoid space (leptomeningitis). Should the air have made a pocket for itself in the substance of the brain, or the brain have been damaged, then brain abscess may result, as occurred in the case reported by Baker and McLean.[38] Should the intracerebral air pocket, thus infected, burst into a ventricle, then a rapidly spreading ependymitis and basal meningitis would follow.

The formation of an intracerebral pneumocephalus either with or without infection, particularly if the portal of entry is valvular, usually produces an increasing intracranial tension with its well recognized symptomatology and pathological changes. Other forms of pneumocephalus are less likely to produce this syndrome, as better absorption of air is likely to occur in those situations.

Secondary delayed rhinorrhœa and pneumocephalus may occur with the breakdown of the early repair tissue as a result of swallowing, coughing, sneezing or other forms of straining. Thus Coleman[33] describes a case in which there had been no immediate leak of cerebro-spinal fluid and yet six weeks after a severe compound depressed fracture of the frontal bone rhinorrhœa occurred and a large pocket of air was found in the frontal lobe. Operation subsequently revealed a communication with the ethmoid sinus, a tube of dura having been caught up in the crevice of the fracture. It is

found generally, however, that when air is present in the frontal lobe, either immediate or delayed rhinorrhœa is by no means a common occurrence; it did not occur in the case here reported.

Rarely, and as a pathological curiosity, air may appear inside the cranial cavity, usually within the brain substance, and following trauma, as the result of infection by anaerobic aerogenic organisms.

CLASSIFICATION.

Once air has entered the cranial cavity, pneumocephalus may thus be found in the following sites.

1. *Subdural Space.*—This is a relatively common finding, and the air may rapidly distend the potential subdural space over an entire cerebral hemisphere and along the falx. The prognosis is good if the brain and leptomeninges remain intact. Air rarely passes from the subdural to the subarachnoid space over the cerebral hemispheres, as the intercommunicating spaces here are too small and the leptomeninges too closely attached to the brain. Entry is usually from the frontal sinus.

2. *Subarachnoid Space.*—Air usually enters the subarachnoid space through an opening at the base of the brain, involving the large cisternæ—that is, from fracture or erosion of the posterior ethmoidal or sphenoidal sinuses. This air may pass directly upwards in the subarachnoid pathways over the cerebral hemispheres or enter the ventricular system via the foramina of the fourth ventricle.

3. *Brain Substance.*—If the pia-arachnoid is torn and the cortex is ruptured, air will pass into the brain, giving rise to a fistulous track or a cyst-like cavity. The entrance to the track may be rapidly walled off by adhesions which prevent air from spreading in the subdural and subarachnoid spaces. With a track which is open or loosely repaired, violent straining may lead to an explosion of air, which enters the frontal lobe and destroys, by distension, part of the brain, which in turn is replaced by air. This air may secondarily damage more brain by pressure before it is absorbed or expelled, especially if the track has a valvular opening. A thin wall of granulation tissue forms around the air and localizes it within the frontal lobe. Later it becomes a smooth-walled cyst. The amount of air in the frontal lobe and the phenomenon of rupture into the ventricle will depend on the size of the original tear, the existence of a valvular opening to the fistula and the frequency and severity of sneezing, coughing or other forms of straining, as may occur in a fit.

4. *Ventricles.*—Air may appear in the ventricles through the track or cavity in the frontal lobe becoming gradually larger, until rupture finally occurs through the wall of the ventricle, or through the subarachnoid space, via the foramina of the fourth ventricle. Direct entry from the sphenoidal sinus through the floor of a distended third ventricle might also occur.

SYMPTOMATOLOGY.

The symptoms associated with pneumocephalus may be divided into three groups.

1. Symptoms resulting from the effects of local trauma. Epistaxis and difficulty in breathing through the nose may be accompanied by loss of smell, temporarily or permanently. Discharge of watery fluid may be complained of (rhinorrhœa) and visual disturbances, with or without diplopia, may be noted.

2. Symptoms resulting from an increase of intracranial pressure. The intracranial pressure is not usually increased very much. When it becomes

raised, the chief symptoms are headache, dizziness, nausea, vomiting and bradycardia. The patient may complain of excruciating pain in the head after sneezing, or other forms of straining. Coma or epileptic seizures may follow, especially if the brain has been damaged by the trauma. There may be mental disturbances. There is rarely any complaint of visual disturbances solely due to the increased pressure.

3. Symptoms resulting from infection. Symptoms occur when organisms from the paranasal sinuses or the mastoid air cells gain entry, either within a few days of injury, or of entry of air, or at a much later stage. The syndromes of meningitis and brain abscess then follow and dominate the clinical picture or are superimposed upon those symptoms and signs already existent.

DIAGNOSIS.

The diagnosis of pneumocephalus can usually be made from a careful history and clinical findings just described. Papillœdema is not usually present, but may be found to a slight degree. Persistent symptoms of increased intracranial pressure after fracture involving the base of the skull or the paranasal sinuses suggest pneumocephalus. A history of injury with a delayed secondary onset of mental symptoms, headaches *et cetera,* as before indicated, will again suggest pneumocephalus. Contralateral signs of cerebral disturbance may be found if the air has passed into the brain substance rather than into the meningeal spaces or ventricles and produced sufficient destruction of the brain or increase of tension. Rhinorrhœa, after an accident, will indicate the presence of this condition or its future development. Tilting the head forwards, with the production of rhinorrhœa, is an absolute diagnostic sign of a fistulous opening into the cranial cavity. If the fistula is small or has a valvular opening, this sign is not constant, though cerebro-spinal fluid may pass out from time to time. Percussion is of little value in the diagnosis of pneumocephalus. Radiological examination of the skull is the one infallible method of diagnosis, and the pictures obtained are very characteristic.

MANAGEMENT.

The recent advances in chemotherapy resulting from the use of the sulphonamide group of drugs have altered the plan of treatment for these cases by enabling infection to be controlled whilst spontaneous cure of rhinorrhœa or absorption of air is awaited, also during and after operations. Once a diagnosis of pneumocephalus has been made, the patient should be kept at rest and warned to avoid excessive coughing, sneezing or other forms of straining which may increase the amount of air inside the cranial cavity. Sedatives and mild aperients may be necessary to control these acts.

In the absence of signs of infection or increasing intracranial pressure no active treatment is necessary at first, but radiological examinations of the skull should be repeated at weekly intervals, in order to determine whether the pneumocephalus is being absorbed or not. Up to six or eight weeks may be allowed for the spontaneous absorption of the air and the closure of the fistulous track. During this time examinations of the bacterial flora of the nose and post-nasal space should be followed by appropriate prophylactic chemotherapy.

The coexistence or appearance of cerebro-spinal rhinorrhœa calls for the immediate prophylactic administration of sulphonamides, although here too time may be allowed for its spontaneous cessation before operation is undertaken. The appearance of signs of infection, even if the air is being absorbed, with or without rhinorrhœa, calls for a full therapeutic course of sulphonamides.

If, on the other hand, the pneumocephalus is not being absorbed, or is increasing, even before signs of increased intracranial tension and infection occur, operation is indicated to close the fistulous track because it is considered certain that infection will follow sooner or later or that signs of increased intracranial pressure will eventuate. Should rhinorrhœa persist or make a delayed appearance, the indication for operation becomes even more imperative. If infection has already occurred, then it is advisable to control it as completely as possible before operation with sulphonamides and to continue their use afterwards until all signs of infection have cleared up. Failure to achieve this result will usually indicate the formation of a brain abscess which will have to be dealt with.

Operative Procedures.

Most of the operations described in the literature have been undertaken for the cure of a coexistent rhinorrhœa, and rarely has it been found necessary to operate for pneumocephalus alone. When operation becomes necessary, the plan of attack will depend upon the site of the communication between the affected air sinus and the pneumocephalus. In the absence of localizing signs of trauma, clinical or radiological, the intrathecal injection of methylene blue may help to indicate the actual site of the fistula in the nose by colouring the leaking cerebro-spinal fluid. Should it be small, accessible and of short duration, conservative treatment by the application of a solution of silver nitrate once or more often has been advocated by Adson.[37] In most cases, however, especially when the onset of the pneumocephalus has been delayed, the opening is valvular and maintained by a tubular prolongation of the meninges through the fracture of the bone into the affected nasal sinus,[37] by a foreign body[39] or by a piece of displaced bone (authors' case); and a major operation is necessary to effect a cure.

Dandy,[24] Cairns[32] and Coleman[33] have advocated an early repair of the torn dura by the use of a direct approach through the frontal sinus for injuries in this region, or of an extradural approach after a unilateral frontal craniotomy for fistulæ leading into the ethmoidal or sphenoidal sinuses. Pieces of *fascia lata* and muscle have been sutured in place to reinforce the closure of the rent in the dura, and Horsley's wax has been used to plug any defect in the bone. Peet[29] has inserted a wick of iodoform gauze for four or five days at the site of rupture of the membranes to make the brain become adherent there and shut off the spaces between the meninges. All recent writers are agreed that, in the presence of infection, the operation area should be liberally sprinkled extradurally with sulphonamide powder.

Adson[37] has found that a bilateral frontal craniotomy, with a coronal scalp incision within the hair-line, gives much better access. The longitudinal sinus can be ligated just above the *foramen cæcum* and the dura elevated from both sides of the cribriform plate at once. This sacrifices the olfactory nerves, but is necessary if the fracture has involved both sides. The fistulous track or tracks are then separated from the line of the fracture, invaginated with fine silk sutures and the suture line reinforced with a piece of muscle. The defect in the bone is filled with Horsley's wax and covered over with a piece of animal membrane, which adheres by pressure.

Gissane and Rank[36] adopted a similar extradural approach without ligating the longitudinal sinus. In order to avoid the use of buried suture material, they divided the fistula with diathermy and applied a graft of high viability from the periosteum of the tibia to the defect in the bone.

More recently Eden[39] described the operative procedures carried out by Taylor in two cases of rhinorrhœa, in one of which there was an associated pneumocephalus in the left frontal lobe. The classical transfrontal intradural

approach for a pituitary tumour was used, and the frontal lobe was elevated off the dura at the site of the fistula into the frontal sinus. The defect in the dura was repaired by a patch of *fascia lata*, made to adhere intradurally by pressure, and that in the bone was ignored. In the other case in which bilateral ethmoidal fistulæ were present, the longitudinal sinus was ligated and both frontal lobes were retracted after incision of the dura across the mid-line, this giving a complete exposure of the torn dura, which was repaired with a large Y-shaped patch of fascia.

Additional room and greater ease may be obtained in retracting the frontal lobe either extradurally or intradurally, by needling the pneumocephalus with a blunt cannula and evacuating the contained air ([39] and authors' case), or air mixed with purulent fluid.[38] The affected frontal lobe then subsides like a punctured balloon.

In the case about to be described none of the above-mentioned techniques could be followed exactly. The nature and extent of the wound and the subsequent sepsis caused much destruction of the anterior portion of the left, and to a lesser degree of the right, frontal lobe and overlying dura, so that a "false" dura was formed, inseparable from the underlying glial scar at the anterior end of the pneumocephalus, and separable from the fractured bones only with difficulty. Thus removal of a sequestrum and fragments of bone from the posterior wall of the frontal sinus at the site of the fistula, along with several displaced pieces of bone from the roof of the left orbit, followed by the insertion of a few silk sutures, had to suffice, with apparently successful results.

The pre-operative and post-operative administration of sulphonamides in adequate dosage is absolutely essential and should bring about a substantial reduction in the mortality rate of 30% mentioned by most authorities. Nor should cure be claimed until clear cerebro-spinal fluid, without cells or increase of protein and under normal pressure, has been obtained by spinal puncture, and repeated radiological examinations have failed to disclose the presence of any air inside the cranium.

REPORT OF A CASE.

The patient, a corporal, aged twenty-two years, was admitted to an Australian camp reception station on November 26, 1941, with a self-inflicted wound of the left infratemporal and frontal regions from a service rifle. He appeared to be quite rational at the time of admission and said that he had just felt "fed-up" and shot himself. A report subsequently received from his unit stated that there was no adequate motive for the attempted suicide. The soldier had stood up to bombing and shelling quite well, but had apparently found the responsibilities of his work as orderly-room clerk too much. It was learnt that he had been worrying for some time prior to the shooting, but he had completed all the work he had been given.

Some hours later he was transferred to an Australian general hospital. By this time he was comatose and cyanosed. There was a wound of entrance in the left infratemporal region and of exit in the right frontal area. Bleeding, together with discharge of brain tissue and cerebro-spinal fluid, was occurring from each opening, and the left eyeball appeared to be destroyed. A "cracked-pot" sound and "crunching" were elicited on percussion over the left frontal area. The right pupil was dilated. The pulse rate was 78 beats per minute and his respirations were 22. At irregular intervals he was having generalized epileptiform fits. He was given one-quarter of a grain of morphine and prophylactic sulphonamide therapy was started after a dressing had been applied to the wounds. X-ray examination (see Figure I) revealed a comminuted fracture of the left frontal bone and of the roof of the left orbit with some indriven fragments of bone. There was also comminution of the right frontal bone with stellate linear fractures extending across the mid-line to the fronto-parietal suture. No aerocele was noted.

Next day his pulse rate was 80 beats per minute. Bleeding from the wounds had almost ceased. Two typical Jacksonian fits, involving the right side of the body, had occurred during the night. He was spitting and urinating into the bed and using bad language. The ophthalmologist to the hospital reported that the globe of the left eye was collapsed and that perforation had occurred.

FIGURE I. Lateral X-ray view of skull showing comminuted fracture of the frontal bone with some indriven fragments involving the frontal sinus and the orbit, on the left side, taken soon after the injury in November, 1941. There is no sign of aerocele.

FIGURE II. Showing dull and confused appearance of patient shortly after admission to hospital in May, 1942. The prosthesis has been removed from his left orbit.

On the third day the patient was conscious, and by November 30 he was described as being more rational and continent of urine. His temperature was normal from this time onwards. On December 3 he was again seen by the ophthalmologist, who advised evisceration of the left eye, and this was carried out on the following day, after intravenous administration of "Pentothal". Healing of the wounds was progressing satisfactorily.

On December 25 the condition of the left orbit was satisfactory, but it was noticed that the left upper lid was swollen and that surgical emphysema was present. The air could be expressed from the lid by digital pressure, but it refilled rapidly when the patient blew his nose. "Snowball" pressure was applied to the lid with cotton wool and by January 2, 1942, the wounds were healed, the eye socket was clean and there was no emphysema in the eyelids. A glass eye was fitted on February 8, and at that time he was symptom-free. The left side of his forehead showed some abnormality where the left frontal bone was comminuted. He was mentally rather simple and childish.

On March 2 he was sent to a base depot to await repatriation. He remained there, well behaved and in good health until May 8 (five and a half months from the time of the original injury), when he was sent to this hospital because he had had some fits that morning which were considered to be hysterical, in view of the fact that certain of his friends had just left "on a draft".

When admitted, he was very confused and unable to give a reliable statement about himself. His temperature was 97·8° F.; his pulse rate was 88 beats per minute; and his respirations numbered 18 per minute. The scars of the through-and-through wound in his left infratemporal and frontal regions were noted. The left eyelids were sunken and there was a prosthesis in the left orbit (see Figure II). During the afternoon the patient remained confused, though he would answer when spoken to. He was incontinent of urine, but not of fæces. Later he was given food, which he vomited. Immediately afterwards he passed urine into the bed, and had a typical generalized epileptic fit. Half an hour after the fit he was conscious and rational.

FIGURE III. Antero-posterior view of skull taken soon after admission to hospital early in May, 1942, showing the vertical and lateral limits of the huge intracranial aerocele.

Next day he was dull and still had a grossly defective memory. His tendon reflexes were exaggerated, especially in the lower limbs; his plantar reflexes were flexor, and his abdominal reflexes were normal. His condition was still further improved on the third day and no further fits had occurred. An intelligence test (Terman revision of the Binet-Simon test) showed him to be of normal intelligence, though it was noted that he was euphoric and facile. It was difficult to get a coherent story from him, and he had to be prompted constantly. He would smile foolishly to himself, and at times had an inadequate sense of his position and failed to take a proper interest in his surroundings. Beyond a ptosis of the left upper eyelid, examination of the cranial nerves showed no abnormality. Taste and smell were appreciated fully.

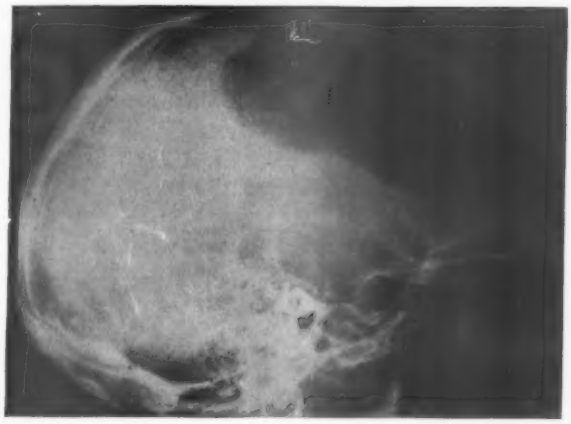

FIGURE IV. Lateral view of skull taken at same time as Figure III, showing the distance to which the aerocele extended posteriorly.

Four days after his admission to hospital the patient felt well and his condition was quite satisfactory. He stated that he had never had any fits previously. A provisional diagnosis of "post-traumatic epilepsy", due to brain scar, was made and routine investigations were begun. The ophthalmologist to the hospital, Major J. Kingsley, reported that there was no papillœdema and that the visual field of the right eye was full. Major G. C. Halliday, ear, nose and throat specialist to the hospital, found no abnormal secretions in his nose or post-nasal space and no evidence of rhinorrhœa. He

detected a mild degree of nerve deafness in the left ear. An X-ray examination of the skull was made by Major K. B. Voss, the radiologist to the hospital, and he reported the presence of an old comminuted fracture of the frontal bone with involvement of the frontal sinuses and the left ethmoidal bone. The posterior wall of the left frontal sinus and a portion of the left supraorbital margin had disappeared. A large amount of air (about 5·0 by 5·0 by 16·0 centimetres) was present in the cranium on the left side (see Figures III and IV).

After consultation with Lieutenant-Colonel C. G. McDonald, the officer in charge of the medical division of the hospital, it was decided not to undertake any active treatment at once, as there were no signs of infection or increased intracranial pressure, the fits had not recurred, and it was hoped that the air would be absorbed spontaneously. Shortly afterwards, on May 17, whilst out of bed, he fainted and vomited twice that night. He reported a blood-stained discharge from his nose, but further examination of his nose did not reveal any active bleeding, although several injected areas were seen in the anterior part of the left side of the septum.

Two days later he complained of a continuous sharp pain in both sides of the upper jaw. Radiological examination of his skull was repeated and showed that the air had disappeared completely (see Figure V). At this time signs of a meningeal reaction were detected. His temperature rose to 99·4° F., and administration of sulphapyridine was begun immediately. The next day he began to vomit and developed hiccup. His temperature was 100·6° F. Spinal puncture was performed and yielded slightly turbid yellowish fluid under normal pressure. Major E. B. Jones, the pathologist to the hospital, reported that it contained eight neutrophile cells, three lymphocytes and several hundred red blood cells per cubic millimetre. The chloride content was 710 milligrammes and the protein content was 45 milligrammes *per centum*. The cerebro-spinal fluid was sterile on culture. Staphylococci, but no pneumococci, were grown from a nasal swabbing.

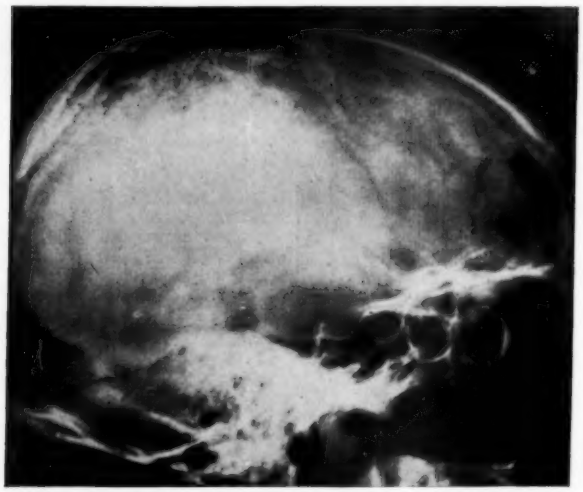

FIGURE V. Lateral view of skull taken one week later. The aerocele had spontaneously disappeared, and the comminuted fracture of the frontal bone, orbit and frontal sinus is visible.

By May 24 the hiccup had become very severe and distressing. Administration of sulphapyridine was stopped after 34 grammes had been administered. Despite this, hiccup persisted, and morphine, carbon dioxide, amyl nitrite and rebreathing into a bag all failed to stop it. A stomach washout was finally given and a large amount of mucus and débris were removed, with relief, but the hiccup did not disappear entirely until May 29. At that time he was apyrexial; he was still euphoric and his general condition was the same as before the onset of the meningitis. A third radiological examination of his skull, made on June 2, indicated that there was again a large amount of air within the cranium, more in amount than previously and loculated in shape (see Figure VI). A further consultation was held with Lieutenant-Colonel C. G. McDonald, and it was concluded that the fistula through which the air was entering the cranial cavity had a valvular communication with the left frontal sinus, that spontaneous cure without operation was unlikely to occur, and that the threat of meningitis would remain. A blood count, however, showed a considerable degree of secondary microcytic anæmia, and as any operative intervention would have to be formidable, it was decided to treat this condition first. By June 29 the anæmia had been relieved and his general mental and physical condition was satisfactory.

On July 2, following premedication with "Alopon" and scopolamine, and under local infiltration anæsthesia, operation was undertaken with the assistance of Lieutenant-Colonel T. Y. Nelson, the officer in charge of the surgical division of the hospital. After a transverse coronal incision was made, a bilateral scalp flap was dissected off the

frontal bone. In the vicinity of the damaged left frontal sinus a small abscess, containing about 0·5 cubic centimetre of pus and a sequestrum, was encountered and evacuated. Unfortunately no bacteriological examination of the pus was made. The remnants of the lining of the frontal sinus were then curetted and sucked away. A left frontal bone flap was raised by connecting six burr holes with a Gigli saw. Considerable difficulty was experienced above the left supraorbital margin, owing to the presence of a displaced fragment of bone from the roof of the left orbit. When the bone flap had been raised, it was found that the underlying dura had been destroyed and was unidentifiable. In its place a false dura had formed, adherent to the brain and the damaged left frontal bone.

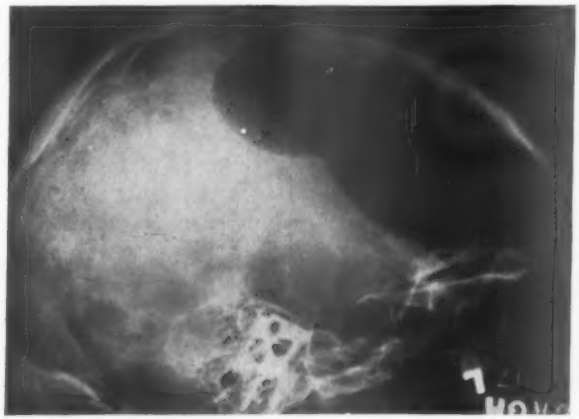

FIGURE VI. Lateral view of skull taken early in June, 1942. The aerocele has reappeared, increased in size and become more loculated.

The brain covered by this false dura was now under considerable tension and began to "walk out". The patient had become very difficult to rouse and his pulse rate had dropped to 48 beats per minute. No air had been encountered extradurally, but when a brain needle was inserted into the left frontal lobe a large cavity filled with air under pressure was entered. With the release of this air the left frontal lobe collapsed. The cavity soon filled up again, however, thus demonstrating the valvular nature of the fistulous opening; and only when the cavity had been laid open through a small incision with the endothermy knife did it remain empty.

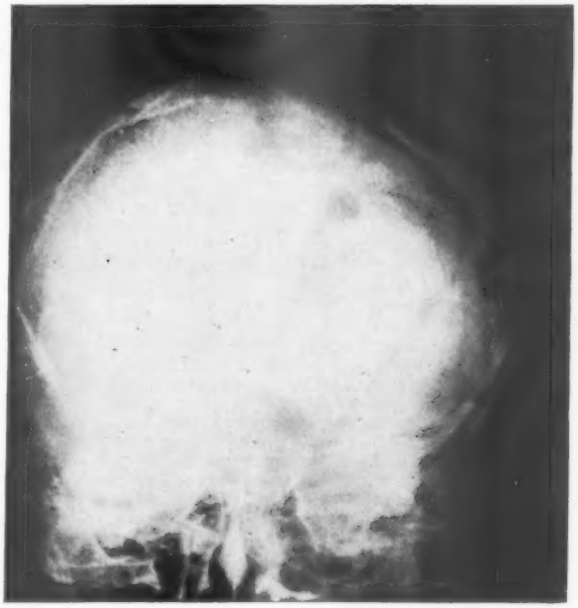

FIGURE VII. Antero-posterior view, taken one month after operation. There is no sign of pneumocephalus.

After the collapse of the left frontal lobe the false dura was dissected away from the remains of the roof of the left orbit and of the left frontal sinus. No large fistula was found between the cavity and the frontal sinus, but it was thought that the air must have entered here through a valve-like opening in the region of the sequestrum already removed. The anterior portion of the damaged *falx cerebri* was also defined, but considerable bleeding was encountered in this vicinity, and the cribriform plate and *crista galli* were not exposed. Two or three fragments of bone from the roof of the orbit were removed during these

procedures, but a large fragment lying vertically against the anterior portion of the falx was not dislodged.

The cavity in the brain was then inspected. It looked like a smooth-walled cyst. It was situated entirely within the left cerebrum and no communication was found between it and the ethmoidal or sphenoidal sinuses. It was filled with about 150 cubic centimetres of normal saline solution, and the opening was tightly closed with silk sutures. After complete hæmostasis a small tube was then drawn by Major G. C. Halliday down the left fronto-nasal duct, out through the external nares until its upper end was just visible. The bone flap was then replaced and the wound closed with a soft rubber drain at each end of the incision. During the later stages of the operation "Sodium Pentothal" was given intravenously by Major S. V. Marshall, the anæsthetist to the hospital, to alleviate pain whilst the false dura was being separated from the bone. At the end of the operation, which had lasted about five hours, the patient's condition was quite satisfactory, although consciousness had not been completely regained. A prophylactic course of sulphadiazine, the first supply of which had just been received at the hospital, was commenced by mouth and continued for six days till 32 grammes had been given.

FIGURE VIII. Lateral view, taken one month after operation, showing position of the bone flap raised at operation, and disappearance of the pneumocephalus.

Convalescence was uneventful. The tube in the fronto-nasal duct drained small amounts of blood and serum for thirty-six hours and was then removed. There was some swelling of the soft tissues in and around the left orbit, but no signs of raised intracranial tension or emphysema appeared. There were no abnormal neurological findings beyond exaggerated tendon reflexes. He was speaking intelligently, had full insight, and was improved mentally. A final X-ray examination on August 2 showed no air in the cranial cavity (see Figures VII and VIII) and the patient was discharged to an Australian convalescent depot, looking very well (see Figure IX), to await repatriation.

FIGURE IX. Photograph of patient taken one month after operation. His alert though euphoric expression contrasts with his appearance seen in Figure II.

His health remained satisfactory until September 1, when he began to vomit, had "some sort of seizure" and became unconscious. After regaining consciousness he was again referred to this hospital for observation and investigation. When admitted he was drowsy and uncooperative. His temperature was 101° F. The tendon reflexes in his lower limbs were exaggerated and his plantar responses were extensor. He appeared to be recovering from an epileptic fit and remembered nothing of the occurrence. Radiological examination of his skull did not reveal any air inside his cranium. Two days later the patient went into *status epilepticus*, which was controlled by paraldehyde *per rectum*. Spinal puncture done some four hours afterwards yielded clear fluid under normal pressure with no cells and a protein content of 45 grammes *per centum*.

During the next three days there was recorded an irregular pyrexia up to 102° F., and further bouts of epileptic fits occurred, despite sedation. No aura or warning was noticed by the patient. Each fit began with a long phase of bilateral extensor rigidity.

Observations by other patients and the nursing staff indicated a difference of opinion as to whether the clonic movements began on the right or left side of his body. The fits were of short duration, and in between times the patient stated he felt well and had no headache. His memory for recent events was very poor, and the only reply obtainable to questions was: "I don't know."

During the night of September 6 he became unconscious, and by 1100 hours next morning his temperature had risen to 105° F. Neck rigidity was marked and Kernig's sign was elicited on each side. The areas of missing bone in both left and right frontal regions were bulging and tense. Spinal puncture was again performed and a pressure of 400 millimetres recorded. Turbid fluid was withdrawn until the pressure had fallen to 180 millimetres. This fluid contained 13,500 neutrophile cells and 1,200 lymphocytes per cubic millimetre, with a few red blood cells. Its protein content was 640 milligrammes *per centum*. Gram-positive intracellular organisms were seen in an immediate smear and later a pure culture of pneumococci was grown. The number of white cells in his blood was 39,600 per cubic millimetre, mainly neutrophile cells.

After gastric lavage, 4·0 grammes of sulphapyridine were put in the stomach and this dose was repeated at four-hourly intervals. On the supposition that an abscess might have formed in the old pneumocephalic cyst and then ruptured into the lateral ventricle, the left frontal lobe was tapped with a brain cannula through the antero-medial burr hole. A cavity was located at a depth of three centimetres and fluid ran out. The first five cubic centimetres were clear, but gradually the remainder became more and more turbid until it resembled that obtained by spinal puncture. About 60 cubic centimetres in all were removed, with relief of tension and improvement in the patient's condition. This fluid contained 1,600 neutrophile cells, 90 lymphocytes and 10 monocytes per cubic millimetre. Its protein content was 150 milligrammes *per centum*. Pneumococci were cultured from it also. After 12·0 grammes of sulphapyridine had been given, vomiting and hiccup became troublesome, and a change-over to sulphadiazine, in similar doses, was made.

FIGURE X. Antero-posterior encephalogram, showing the large left lateral ventricle, with the diverticulum from the anterior horn, produced by traction from the cicatrix in the left frontal lobe and replacing the pneumocephalic cavity. The third ventricle and right lateral ventricle can be seen, both larger than normal.

On September 8 spinal puncture was repeated. The pressure was 280 millimetres and the cerebro-spinal fluid was still turbid. The fluid contained 14,800 neutrophile cells, 4,000 lymphocytes and 500 monocytes per cubic millimetre, but was sterile when cultured. The temperature was 102·4° F., but the patient was conscious and could be roused. The right eye exhibited gross nystagmus and external strabismus. There were irregular athetotic movements of the limbs, most marked in the left lower limb. Left ventricular tap was again performed and the fluid was found to be nearly clear; 15 cubic centimetres were removed, with relief of tension in the decompression sites. Sulphadiazine administration was continued in doses of 2·0 grammes every four hours. Thereafter the patient's condition gradually improved as the infection subsided by lysis. On September 10 spinal puncture indicated a pressure of only 140 millimetres. The cerebro-spinal fluid was slightly turbid and yellow. It contained 840 cells per cubic millimetre, but was sterile on culture. The white cell count of the blood was 12,000 per cubic millimetre.

On September 12, although the cerebro-spinal fluid was still yellow, the cell count was only 376 per cubic millimetre, and two days later, after a total of 88·0 grammes of sulphadiazine had been given, the meningitis appeared to have subsided and no further fits had occurred. Examination of his nose and throat by Major G. C. Halliday once again failed to reveal any abnormality, and from swabbings only staphylococci were grown. On September 29 another spinal puncture indicated a pressure of 140 millimetres and yielded clear fluid containing 11 cells and 90 milligrammes of protein per cubic millimetre.

FIGURE XI. Left lateral encephalogram, showing the greatly enlarged anterior horn of the left lateral ventricle, pulled out as a diverticulum into the frontal lobe and extending downwards to the posterior ethmoidal region, but not reaching the frontal sinus. Compare with the view of the pneumocephalus seen in Figure VI.

In an endeavour to locate an abscess elsewhere in the left or right frontal lobes as the focus for the recent attack of meningitis, encephalography was performed on October 19, when 100 cubic centimetres of cerebro-spinal fluid were replaced with oxygen. The fluid was clear and contained only five lymphocytes, but still had a protein content of 90 milligrammes per cubic millimetre. Antero-posterior and lateral radiographs were taken (see Figures X, XI and XII), and revealed a large left lateral ventricle with a diverticulum extending into the left frontal lobe and down to the posterior ethmoidal region. The third ventricle was bigger than normal and not quite in the mid-line, and a generalized enlargement of the right lateral ventricle was seen. Only a slight reaction followed this procedure, and he was allowed up two days later. On October 25 the patient was clinically well and normal mentally. His memory was excellent for past events. His sense of smell seemed defective in each nostril and there was still some coarse nystagmus of the right eye when he looked to the right. He was able to do odd jobs in the ward, and busied himself with occupational therapy. No further fits had occurred.

FIGURE XII. Right lateral encephalogram, showing the generalized enlargement of the right lateral ventricle, mainly in the anterior horn, which has "wandered" outwards in response to traction from the cicatrix in the right frontal lobe.

Discussion.

Many of the pathological and clinical features mentioned in the review are illustrated by the case just reported, together with some of the peculiar and difficult complications which may be encountered in this condition.

The following points appear to be particularly worthy of comment:

1. The primary recovery of the patient was remarkable considering the severity and extent of the initial trauma, which necessitated evisceration of the left eye. The early appearance of a euphoric state and a relative insensibility to pain, associated with cortical destruction in the frontal areas, may have helped considerably. This lack of emotional response was evident and assisted his rapid recovery after the operation and during the subsequent attack of pneumococcal meningitis.

2. The damage to the frontal lobes, caused by the bullet, is regarded as an important factor in eliminating his suicidal tendencies and worries, which never recurred after the trauma. This fact may be taken as human experimental evidence of the value of prefrontal lobotomy or lobectomy, recently advocated by some writers for the relief of certain mental disorders.

3. The minor degree of cognitive defect, as compared with the amount of affective disorder, despite the traumatic destruction of the left frontal lobe and its subsequent disruption and distension with air, corroborates observations made elsewhere that serious mental deterioration need not necessarily result from operations for removal of the frontal lobes.

4. The time of formation of the pneumocephalus is problematical. It was not present at the first radiological examination (see Figure I). It may have coincided with the appearance of emphysema in the left upper eyelid one month after injury; but it is considered more likely that the air entered the left frontal lobe from the left frontal sinus early in May, 1942, about the time of the first recorded fits, being either the cause or the result of their occurrence. The reason for the complete disappearance of the air one week later (see Figure V) became obvious when the valvular nature of the fistulous opening was demonstrated at operation, as the cavity rapidly refilled with air after its initial evacuation.

5. The absence of any proven rhinorrhœa with such a large pneumocephalus was unusual and seemed to indicate that the air entered directly into the frontal lobe and that the subarachnoid spaces had been closed off earlier.

6. The sudden reappearance of fits two months after an uneventful post-operative convalescence was regarded at first as being due to traction from the cicatrices in the frontal lobes, especially as a spinal puncture two days later did not show any evidence of infection or increased intracranial pressure and radiological examination did not reveal any recurrence of pneumocephalus. When the ensuing *status epilepticus* was followed by pneumococcal meningitis, it was thought that some residual abscess, either in the old pneumocephalic cavity or in the vicinity of the damaged left frontal sinus, had ruptured into the lateral ventricle or the general subarachnoid space. The former postulate was soon eliminated by the early flow of clear cerebro-spinal fluid and the failure to obtain pus when the left frontal lobe was needled. Abscess formation elsewhere was subsequently shown to be unlikely when encephalography (see Figures X, XI and XII) did not reveal any space-consuming lesion.

7. The portal of entry for the pneumococci must remain undetermined, as nasal and post-nasal bacteriological and clinical examinations never yielded this organism nor revealed any communication between the nasal and cranial cavities. Unfortunately the pus found at operation near the sequestrum from the left frontal sinus was not cultured. Despite the known existence of a brain cicatrix with a compensatory ventricular diverticulum in the left frontal lobe, it is felt that the second bout of fits was the precursor of this attack of meningitis, as no further fits occurred once the meningitis was controlled.

8. Finally, the efficacy of the drug sulphadiazine in controlling this virulent form of meningitis was ably demonstrated, especially after severe vomiting, dilatation of the stomach and hiccupping had made further administration of sulphapyridine impossible.

SUMMARY.

1. The history and bibliography of pneumocephalus are reviewed.

2. Its pathology, symptomatology and diagnosis are described.

3. Classification and terminology according to the site of the air are advocated.

4. A routine for general management is indicated, and various therapeutic operative procedures are mentioned.

5. A complicated case of pneumocephalus, associated with compound comminuted fracture of the left orbital cavity, frontal bone and frontal sinus, with loss of the left eye, with damage to the frontal lobes and with traumatic epilepsy and meningitis, following a self-inflicted gunshot wound of the left temple, is presented.

6. Many unusual and puzzling features, with comments on their significance and their treatment, are discussed.

ACKNOWLEDGEMENTS.

The thanks of the authors are gratefully extended to:

1. Lieutenant-Colonel C. G. McDonald and Lieutenant-Colonel T. Y. Nelson, the officers in charge of the medical and surgical divisions of the hospital respectively, and the different specialists mentioned in the text for their assistance in solving the diagnostic, operative and post-operative problems involved in this case.

2. Dr. H. Yassky, the director, and Dr. Henry Wigderson, the neurosurgeon, of the Hadassah Medical Organization, Jerusalem, for making possible the compilation of the bibliography and affording access to the literature.

3. Private L. R. Withers, of the Australian general hospital, who prepared the photographs from the radiological films for publication.

4. The Deputy Director of Medical Services, Australian Imperial Force (Middle East), and the Director-General of Medical Services, Allied Land Forces, for permission to publish this article.

REFERENCES.

(1) H. Chiari: "*Ueber einen Fall von Luftansammlung in den Ventrikeln des menschenlichen Gehirns*", *Zeitschrift für Heilkunde*, Volume v, 1884, page 383.

(2) W. H. Luckett: "Air in the Ventricles of the Brain Following a Fracture of the Skull: Report of a Case", *Surgery, Gynecology and Obstetrics*, Volume xvii, 1913, page 237.

(3) E. Wolff: "*Luftansammlung im rechten Seitenventrikel des Gehirns (Pneumozephalus)*", *Münchener medizinische Wochenschrift*, Volume lxi, 1914, page 899.

(4) J. Duken: "*Ueber zwei Fälle von intrakranieller Pneumatocele nach Schussverletzung*", *Münchener medizinische Wochenschrift*, Volume lxii, 1915, page 598.

(5) L. Kredel: "*Die intrazerebrale Pneumatokele nach Schussverletzungen*", *Zentralblatt für Chirurgie*, Volume xlii, 1915, page 649.

(6) A. Wodarcz: "*Zur Kasuistik der intracraniellen Pneumatozele*", *Münchener medizinische Wochenschrift*, Volume lxii, 1915, page 968.

(7) E. H. Skinner: "Intracranial Aerocele", *The Journal of the American Medical Association*, Volume lxvi, 1916, page 954.

(8) F. Bruenig: "*Uebergrosse lufthaltige Gehirncyste nach Schussverletzung*", *Beiträge zur klinische Chirurgie*, Volume cvii, 1917, page 432.

(9) G. Cotte: "*Hydro-pneumatocele traumatique du crâne*", *Bulletins et mémoires de la Société des chirurgiens de Paris*, Volume xliii, 1917, page 865.

(10) D. Hansemann: "*Ueber Pneumocephalus*", *Virchows Archiv für Pathologie, Anatomie und für klinische Medizin*, Volume ccxxiv, 1917, page 75.

(11) G. W. Holmes: "Intracranial Aerocele", *American Journal of Roentgenology*, Volume v, 1918, page 384.

(12) Reisinger: "*Ueber intracranielle, aber extracerebrale Pneumatocele nach Schussverletzungen*", *Beiträge zur klinische Chirurgie*, Volume cix, 1918, page 129.

(13) R. Glenard: "Traumatic Aerocele of the Brain", *La presse médicale*, Volume xxvii, 1919, page 123.

(14) Goldammer: "*Ueber die traumatische Luftcyste des Gehirns nach Schussverletzungen*", *Deutsche Zeitschrift für Chirurgie*, Volume cxlix, 1919, page 86.

(15) R. J. May: "Case Showing Air within Cranial Cavity", *American Journal of Roentgenology*, Volume vi, 1919, page 190.

(16) H. E. Potter: "Case of Hydropneumocranium with Air in Ventricles", *American Journal of Roentgenology*, Volume vi, 1919, page 12.

(17) A. S. Doyle: "Traumatic Pneumocranium", *American Journal of Roentgenology*, Volume viii, 1921, page 73.

(18) G. Horrax: "Intracranial Aerocele Following Fractured Skull", *Annals of Surgery*, Volume lxxiii, 1921, page 18.

(19) W. G. Spiller: "Aerocele of Brain", *Medical Clinics of North America*, Volume v, 1921, page 651.

(20) N. Hansson: "A Case of Fracture of the Cranium with Accumulation of Air in the Cranial Cavity", *Acta radiologica*, Volume i, 1921-1922, page 42.

(21) F. C. Grant: "Intracranial Aerocele Following Fracture", *Surgery, Gynecology and Obstetrics*, Volume xxxvi, 1923, page 251.

(22) Schloffer: "Pneumocephalus after Fracture of Skull", *Archiv für klinische Chirurgie*, Volume cxxvii, 1923, page 731.

(23) F. R. Teachenor: "Pneumoventricle of the Cerebrum", *Annals of Surgery*, Volume lxxviii, 1923, page 561.

(24) W. E. Dandy: "Pneumocephalus (Intracranial Pneumatocele or Aerocele)", *Archives of Surgery*, Volume xii, 1926, page 949.

(25) A. Krogius: "*Luft in den Seitenventrikeln des Gehirns (Pneumatocephalus) nach einer Basisfraktur*", *Acta chirurgica Scandinavica*, Volume lx, 1926, page 291.

(26) S. C. Davidson: "Traumatic Pneumoventricle of Cerebrum", *American Journal of Roentgenology*, Volume xvii, 1927, page 447.

(27) T. Eggers: "*Pneumocephalus und Liquorrhœa nasalis nach Schaedelfraktur*", *Archiv für klinische Chirurgie*, Volume cxliv, 1927, page 121.

(28) F. R. Teachenor: "Intracranial Complications of Fracture of Skull Involving Frontal Sinus", *The Journal of the American Medical Association*, Volume lxxxviii, March 26, 1927, page 897.

(29) M. M. Peet: "Symptoms, Diagnosis and Treatment of Acute Cranial and Intracranial Injuries", *New York State Journal of Medicine*, Volume xxviii, May 15, 1928, page 555.

(30) S. W. Miller, R. N. Klemmer and P. O. Snoke: "Traumatic Pneumocephalus", *The Journal of the American Medical Association*, Volume xcvi, 1931, page 172.

(31) D. Lewis: "Practice of Surgery", Volume xii, 1932, pages 310-319.

(32) H. Cairns: "Injuries of the Frontal and Ethmoidal Sinuses, with Special Reference to Cerebrospinal Rhinorrhœa and Aeroceles", *The Journal of Laryngology and Otology*, Volume lii, September, 1937, page 589.

(33) C. C. Coleman: "Fracture of the Skull Involving the Paranasal Sinuses and Mastoids", *The Journal of the American Medical Association*, Volume cix, November 13, 1937, page 1613.

(34) S. A. Friedberg and T. C. Galloway: "Spontaneous Cerebrospinal Rhinorrhœa", *Annals of Otology, Rhinology and Laryngology*, Volume xlvii, September, 1938, page 792.

(35) W. S. Brock: "Injuries of Skull, Brain and Spinal Cord", 1940, pages 204-206.

(36) W. Gissane and B. K. Rank: "Post-Traumatic Cerebrospinal Rhinorrhœa, with Case Report", *The British Journal of Surgery*, Volume xxvii, 1940, page 711.

(37) A. W. Adson: "Cerebrospinal Rhinorrhœa: Surgical Repair of Craniosinus Fistula", *Annals of Surgery*, Volume cxiv, 1941, page 697.

(38) G. S. Baker and A. R. McLean: "Cerebrospinal Rhinorrhœa Associated with Pneumocephaly, Pneumococci Meningitis and Abscess of the Brain (Report of a Case)", *Proceedings of the Staff Meetings of the Mayo Clinic*, Volume xvi, November 19, 1941, page 746.

(39) K. Eden: "Traumatic Cerebrospinal Rhinorrhœa", *The British Journal of Surgery*, Volume xxix, 1942, page 299.

SOME ASPECTS OF ROYAL AIR FORCE CASUALTIES.[1]

By E. T. Cato,
Wing Commander, Royal Australian Air Force.

WITH NOTES ON THE BACTERIOLOGY OF WAR WOUNDS.

By E. M. Darmady,
Squadron Leader, Royal Australian Air Force.

The surgery of modern warfare presents many problems, both for the physician and surgeon. Of these, shock has remained not only the most difficult to treat but also the biggest stumbling block in the way of operative interference. We feel strongly, therefore, that in the past some airmen would have survived if more time had been spent on resuscitation before operation.

In assessing the degree of shock, four criteria were used: firstly, blood pressure; secondly, the appearance of the patient; thirdly, pulse rate; and fourthly, hæmoglobin value. Of these, the first two have appeared to be the most reliable, and at no time was operative procedure considered if the systolic blood pressure was below 100 millimetres of mercury. To combat shock, in our opinion complete immobility must be secured, warmth must be applied, morphine must be given, and fluid loss must be replaced, in that order.

As far as possible the patient is sent straight to the ward. No attempt is made to undress him or to carry out detailed examination until his condition is satisfactory. The warmth has been obtained by large electric cradles, electric blankets and hot water bottles. The cradle requires constant supervision, since serious burns have been known to occur from time to time, and this treatment may also increase fluid loss by excessive perspiration and thus add to the shock of the already shocked patient.

Fluid loss is made good by whole blood, stored whole blood, plasma or serum, and it is essential to be guided by blood pressure and hæmoglobin estimations. For those who are badly shocked it is usually necessary to cut down on the vein, and the use of an apparatus which is capable of producing positive pressure is an absolute necessity.

As a routine 3,000 units of tetanus antiserum, two grammes of sulphapyridine soluble and one-third of a grain of morphine and one one-hundred-and-fiftieth of a grain of scopolamine are given intramuscularly. If extensive damage to tissue, particularly muscle, has taken place, gas gangrene antiserum has also been injected.

When operative procedure was delayed more than four hours a further two grammes of soluble sulphapyridine have been given. In all cases blood pressure, temperature and pulse rate have been charted at half-hourly intervals.

In view of the recent article by Radley Smith,[1] who showed that 3,000 units of tetanus antiserum are not sufficient to prevent tetanus unless protection is given by tetanus toxoid, it is pointed out that immunization to tetanus is imperative on entry to the services, and has been found effective in practice.

[1] Accepted for publication on January 6, 1943.

As soon as the shock has been overcome it is essential to make a most detailed examination. The importance of making an X-ray examination cannot be sufficiently stressed, as will be shown later, not only to detect and localize the presence of foreign bodies but also for the diagnosis of fractures, many of which may escape unnoticed.

SOFT TISSUE WOUNDS.

The majority of soft tissue wounds are caused by fragments of cannon shells, machine-gun bullets or portions of fusilage.

It is essential in all cases: (*a*) to carry out a thorough excision of dead tissue with the minimum excision of skin edges; (*b*) to remove the larger foreign bodies; (*c*) to sprinkle all parts of the wound with sulphanilamide or its derivatives (we found that up to 20 grammes might be used without ill effect).

For uncomplicated aircrew casualties we would advise primary closure of all wounds involving skin and soft parts only, provided that it is possible to operate within twelve to fourteen hours of the injury.

Foreign bodies should be removed as soon as possible, but when this demands extensive operative procedure involving damage to tissue it is better to pack the wound with "Vaseline" gauze and to extract them at a later date.

In wounds with gross destruction of tissue the above scheme is applied, except that a thorough *débridement* is carried out and the wound is packed with "Vaseline" gauze and a padded plaster is applied and kept on for eight to fourteen days or longer. A careful watch is kept on the temperature and pulse during this period, and at no time should there be any hesitation in changing the plaster.

We have found that when primary suture was not possible, secondary suture might be performed between six and twenty days. In our experience, however, with extensive loss of tissue this is not always possible, and in these cases therefore skin grafting should be contemplated as soon as practicable. In our view it is essential to be guided by the bacteriologist before undertaking either of these measures, since the appearance of the wound in no way indicates the presence or absence of specific organisms, many of which seriously interfere with healing or the taking of grafts. It is our practice to swab every area before skin grafting or secondary suture. In the event of undesirable organisms being present, four days' local treatment with sulphanilamide or its derivatives is usually sufficient to "sterilize" the area.

The type of graft depends on the site and size of the area involved and on the condition of the granulating tissue. For areas which required subsequent mobility, Ollier-Thiersch grafts are advisable. For areas with large tissue loss requiring strength of surface, pinch grafts are more suitable.

There was a 1% incidence of gas gangrene in all patients treated. A careful watch must be kept at all times for the presence of gas gangrene, for in our series five cases were found and one patient subsequently died.

A sergeant pilot with severe damage to the elbow joint and upper arm was admitted to hospital twelve hours after injury. The patient was very shocked, and another three hours were spent on resuscitation before operation could be performed. The patient almost died on the table and the complete operation had to be discontinued. He died some hours later, and at post-mortem examination well established gas gangrene was found and confirmed microscopically. The speed with which gas gangrene can develop is worthy of note.

In the remaining four successful cases treatment consisted of the removal of all affected muscles, and the administration of full doses of sulphapyridine (not less than thirty-eight to forty grammes in each) and gas gangrene antiserum (30,000 units). The chief value of gas gangrene antiserum probably lies in its use as a prophylactic measure. Recent work on gas gangrene has,

however, shown that sulphadiazine is superior to sulphapyridine. It is therefore suggested that this substance should be substituted in future, particularly as a prophylactic measure. Gas gangrene serum should be used as an adjuvant when tissue loss is severe.

JOINT INJURIES.

The value of using sulphapyridine in joint injuries cannot be sufficiently emphasized and is well illustrated by the following two histories.

Sergeant C. was admitted to hospital with a machine-gun bullet wound through the right knee joint, sustained seven hours previously. There were a small entrance wound lateral to the patella and a large wound in the popliteal space. Operation was performed. This consisted in: (*a*) excision and primary suture of the entrance wound; (*b*) irrigation of the joint space with aqueous acriflavine 1 in 1,000 and subsequent insufflation with sulphapyridine powder; (*c*) extensive *débridement* of the popliteal space followed by application of sulphapyridine powder and light packing with "Vaseline" gauze. A plaster spica was applied with the knee in almost full extension. Sulphapyridine soluble (two grammes) was given before operation and one gramme during operation. Twenty-eight grammes of sulphapyridine were given orally after operation. The patient was afebrile after two days. There was almost full and painless movement after eight weeks. A large Ollier-Thiersch skin graft was put on the popliteal space five weeks after operation. This patient returned subsequently to full flying duties.

Sergeant S. was admitted to hospital with a machine-gun bullet wound of the left knee joint and a compound comminuted fracture of the left patella. The machine-gun bullet was lodged in the knee joint. Six hours after injury an operation was performed. The skin edges and the patella were excised and the quadriceps was repaired. Primary closure of the knee joint was carried out after removal of the foreign body. Sulphapyridine was put into the joint space and a plaster spica was applied. Sulphapyridine, grammes eleven, was given orally every six hours for six days. The patient was afebrile after three days. The wound healed by first intention. There was full extension with flexion to 100° in seven and a half weeks. This patient also returned to full flying duties.

In our opinion the use of sulphapyridine or its derivatives is essential in the treatment of all wounds involving joints. Primary closure is desirable when there is not great loss of tissue and the skin edges can be brought comfortably together. When this is not possible, or there is damage to bone, primary suture is contraindicated and the joint should be left open. Immobilization in padded plaster is, of course, imperative, and the plaster should extend well above and below the injury, the limb being immobilized in the position of function.

UNCOMPLICATED COMPRESSION FRACTURE OF THE SPINE.

Uncomplicated compression fracture of the spine appears to be of especial interest to the Royal Air Force since it so frequently follows an aircraft crash. In our series there were in eighteen months 28 crush fractures, exclusive of fractures of the cervical spine. Another hospital reported 60 in a similar period.

We have found that unless one is constantly alive to its possibilities this fracture may go undiagnosed, as, for example, one in our own series which was not "spotted" for four days and two others in patients transferred from other hospitals at the end of four and six days respectively. Another was seen after twenty-eight days, and the patient was apparently suffering only from a stiff neck. For this reason routine X-ray examination of the spine is to be advised in all cases of doubt. The position of the fractures is usually in the low dorsal or high lumbar region, those of the cervical area being relatively less common.

It is essential to obtain early efficient reduction and effective immobilization in plaster. Reduction is best carried out at about four to six days after the injury. This gives time for the spasm of the surrounding muscles

to disperse and allows the patient to recover from the inevitable shock which accompanies the fracture, provided always that there are no physical signs of damage to the central nervous system.

Two techniques were adopted: the Watson Jones[2] two-table method for low dorsal or high lumbar fractures and the Davis suspension technique (Figure I) for low lumbar and high dorsal fractures. For the latter full anæsthesia is essential. A minority required operative interference, this being limited to a few in which the spine was fractured by hyperextension and subsequent locking of the intraarticular facets as opposed to simple compression. In the accompanying table is shown the frequency of this fracture over an eighteen months period in one hospital alone.

BURNS.

Burns are one of the most important casualties occurring in the Royal Air Force because of the skilled personnel involved. All burns are accompanied by extreme degrees of shock. For this adequate treatment already outlined is imperative.

The extent of the areas involved present two problems: (*a*) the extreme loss of body fluids and its subsequent replacement; (*b*) the prevention and control of sepsis with its coexisting toxæmia.

In addition, therefore, the use of serum, plasma and saline solution and glucose as an intravenous infusion is essential. The last mentioned is especially indicated because of the extensive liver damage.

FIGURE I.

In combating the risk of superadded sepsis, no matter what type of treatment is adopted, meticulous care must be taken by all members of the staff, not only in the initial cleansing, but in all subsequent dressings and treatment. Adequate masks, sterile gloves and gowns should be worn on all occasions, and as far as possible the patients should be isolated to prevent any risk of cross-infection.

In selecting the type of treatment one must be guided by the extent of the burn and the particular area involved. Of the innumerable methods available we have tried the following: (*a*) tannic acid treatment; (*b*) triple dye treatment; (*c*) the Bunyan-Stannard bag treatment; (*d*) sulphanilamide powder, *tulle gras* and total immersion saline baths.

Tannic acid treatment was used in the early part of the war and, provided that the initial cleansing was adequate, it was found satisfactory on flat non-mobile surfaces. It is, in our opinion, definitely contraindicated in areas such as hands, face and any flexures demanding early movement. In addition the hard coagulum prevents the early recognition of pus beneath this covering. McIndoe[3] has already stressed the dangers of contracture following this type of treatment, especially with regard to fingers, where it often resulted in the "clawed hand".

Triple dye has similar disadvantages and because of this is an unsatisfactory method.

The Bunyan-Stannard bag treatment, although a distinct improvement on the methods above, demands too constant and frequent nursing supervision

Name.	Level.	Cause.
Cervical spine:		
Sgt. H.	Fourth cervical vertebra.	Aircraft crash.
P.O. G.	Subluxation of fifth and sixth cervical vertebræ.	Aircraft crash.
A.C.2 B.	Fifth cervical vertebra.	Fall from window.
P.O. G.	Seventh cervical vertebra and dislocation of intraarticular facets.	Aircraft crash.
A.C.2 I.	Second cervical vertebra.	Motor accident.
P.O. B.	Sixth cervical vertebra.	Aircraft crash.
L.A.C. C.	Dislocation of fourth cervical vertebra.	Aircraft crash.
A.C.2 G.	Fifth and sixth cervical vertebræ	Aircraft crash.
Lumbar and dorsal spines:		
P.O. S.	Fifth lumbar vertebra.	Parachute landing.
L.A.C. M.	Second lumbar vertebra.	Bomb explosion.
F.O. Mc.	Fourth lumbar vertebra.	Parachute landing.
P.O. B.	First lumbar vertebra.	Parachute landing.
P.O. Mc.	Transverse processes of first, second, third and fourth lumbar vertebræ.	Aircraft crash.
L.A.C. T.	Second, third and fourth lumbar vertebræ.	Aircraft crash.
F.Lt. O.	First and second lumbar vertebræ.	Aircraft crash.
Sgt. P.	Third lumbar vertebra.	Aircraft crash.
P.O. W.	First lumbar vertebra.	Aircraft crash.
A.C. S.	First lumbar vertebra.	Crushed under barrage balloon.
P.O. H.	Right transverse process of first and second lumbar vertebræ.	Aircraft crash.
Sgt. Mc.	Transverse process (right) of third lumbar vertebra.	Bomb explosion in plane.
Sgt. B.	First lumbar vertebra.	Aircraft crash.
L.A.C. N.	Second lumbar vertebra.	Fell off ladder.
Sgt. R.	Transverse process of third lumbar vertebra.	Aircraft crash.
A.C.2 E.	First lumbar vertebra.	Fall from height.
F.O. M.	First lumbar vertebra with paraplegia.	Aircraft crash.
Sgt. N.	First lumbar vertebra.	Parachute landing.
Sgt. G.	First lumbar and twelfth dorsal vertebræ.	Aircraft crash.
A.C.2 O.	First lumbar and twelfth dorsal vertebræ.	Fall from height.
P.O. S.	First lumbar vertebra.	Fall from height.
P.O. A.	Second and third lumbar vertebræ.	Aircraft crash.
Cpl. F.	Second lumbar vertebra.	Aircraft crash.
Cpl. B.	Second lumbar vertebra.	Motor accident.
L.A.C. S.	First lumbar and twelfth dorsal vertebræ.	Aircraft crash.
Cpl. A.	Ninth and tenth dorsal vertebræ.	Aircraft crash.
Cpl. D.	Twelfth dorsal vertebra.	Aircraft crash.
A.C.1 T.	Twelfth dorsal vertebra.	Bomb explosion.
L.A.C. S.	Ninth dorsal vertebra.	Aircraft crash.
Sgt. R.	Fourth and fifth dorsal vertebræ.	Aircraft crash.
F.Lt. P.	Ninth dorsal vertebra.	Motor accident.
Sgt. F.	Seventh and eighth dorsal vertebræ.	Aircraft crash.
F.Lt. B.	Ninth and tenth dorsal vertebræ.	Aircraft crash.
P.O. R.	Fifth and sixth dorsal vertebræ.	Aircraft crash.
L.A.C. Mc.	Twelfth dorsal vertebra.	Aircraft crash.
Sgt. T.	Eighth dorsal vertebra.	Aircraft crash.
Sgt. B.	Twelfth dorsal vertebra.	Aircraft crash.
Sgt. M.	Twelfth dorsal vertebra.	Aircraft crash.
Sgt. T.	Fourth, fifth and sixth dorsal vertebræ.	Aircraft crash.
F.Lt. D.	Fifth dorsal vertebra.	Aircraft crash.
P.O. S.	Seventh dorsal vertebra.	Aircraft crash.
A.C.1 I.	Fourth dorsal vertebra.	Motor accident.
P.O. B.	Fourth dorsal vertebra.	Aircraft crash.
F.Lt. B.	Tenth dorsal vertebra.	Aircraft crash.
F.O. B.	Eighth dorsal vertebra.	Aircraft crash.
L.A.C. B.	Second dorsal vertebra.	Aircraft crash.
Sgt. G.	Fifth dorsal vertebra.	Aircraft crash.
Sgt. Mc.	Seventh dorsal vertebra.	Aircraft crash.
Sgt. F.	Seventh dorsal vertebra.	Aircraft crash.
L.A.C. Mc.	Fifth and sixth dorsal vertebræ.	Lifting heavy weights.
P.O. D.	Eighth dorsal vertebra.	Aircraft crash.

to be adopted universally. For this reason the treatment outlined below is considered more efficacious. The bag is, however, useful as a first-aid dressing because it relieves pain and helps to prevent secondary infection.

The method we have found satisfactory is as follows. Firstly and most important, thorough cleansing of the affected parts is carried out. Secondly, a fine covering of powdered sulphanilamide or its derivatives is applied until

an appearance of "hoar frost" is obtained. Thirdly, the area is covered with one layer of *tulle gras*[1] and then sterile gauze. We felt that this was not only comforting to the patient but also allowed early movement of all mobile parts.

FIGURE II.

As soon as practicable, total immersion in a warm sterile saline bath was instituted (Figure II). This allowed: (*a*) the mechanical washing away of débris; (*b*) the easy removal of the dressing; (*c*) the sense of comfort to the patient; (*d*) active exercises of all mobile parts, which we consider essential for full and early restoration of function.

If the burnt area is large, the patient should be immersed daily in a saline bath, but in our opinion baths should not be used until shock has passed completely. The early restoration to full function is greatly aided by the use of a suitable early skin graft as soon as a healthy granulating area has been obtained. For this purpose the precautions to obtain sterility which we have already stressed, must be applied.

The increased interest in the subject of burns now being displayed and the improved results which have followed, will be one benefit which war has brought to "suffering humanity".

FIGURE III.

FROST-BITE.

The distressing condition of frost-bite usually affects the hands only, except where prolonged exposure has occurred, as in forced landing into the sea. From all standpoints the condition is extremely serious, since some of these men are unable to return to operational flying. Wireless operators are frequently affected, since they are in the habit of removing their gloves in order to facilitate their work in the air.

[1] *Tulle gras* can be made as follows. Curtain net, mesh of two millimetres, is cut into pieces nine centimetres square. These are placed in a tin box of slightly larger size with greaseproof paper between each square of material. The box is then filled with the following material: soft paraffin, 96 parts; balsam of Peru, 2 parts; halibut oil, 2 parts. Sufficient to impregnate and cover the material completely after sterilization must be used.

The recognition of the condition is well illustrated in Figure III. There is usually little feeling in the tips of the fingers, and pain sensations are completely inhibited. The backs of the hands are œdematous, and formation of bullæ is seen on the dorsal areas of fingers and hands.

The treatment can be outlined as follows:

1. Gradual warming of affected parts should be allowed to occur naturally. No heat should be applied.

2. The expression of the fluid from the bullæ must be carried out under strict aseptic precautions, and subsequent applications of 1 in 1,000 brilliant green must be made.

3. The injection of the stellate ganglion in the case of the hands with 1% "Novocain" solution rapidly brings back sensation in most cases and also abolishes the pain, which may be intense. This supports the theory that these disturbances of sensation in frost-bite are due to local relative ischæmia occasioned by vaso-spasm.

NOTES ON BACTERIOLOGY OF WAR WOUNDS.

(E. M. Darmady.)

The gross infection of wounds which appeared to be one of the greatest problems of the last war, does not appear to be so in this. This is probably due to three factors. First come the prophylactic measures instituted in the Air Force as a routine; secondly, there is the comparative speed with which casualties are transferred to hospital; and, thirdly, the use of the sulphanilamide groups of drugs.

Although history will finally confirm the use of antitetanus toxoid, it appears extremely possible that tetanus will not be one of the feared causes of mortality. As has already been stated, however, it is the practice to give tetanus antiserum on a patient's admission to hospital. The prophylactic use of gas gangrene serum, however, does not appear to have the beneficial results of tetanus antiserum, although experimental evidence shows very clearly that sulphanilamide derivatives, both given orally and applied locally, have extremely lethal action on this group of organisms. It is probable that more frequent use of this compound will reduce mortality even further. The application of sulphanilamide powder to the wounds as a first-aid dressing is therefore even more important than ever.

For these reasons the wounds arrive at the hospital for the most part sterile. It is after the patient's admission to hospital that the bacteriologist's work really begins, since increasing weight of evidence shows that wounds are more commonly infected here than was formerly imagined.

So important has this work become that it has formed the subject of a special Medical Research Council memorandum.

Bacterial contamination in wounds appears to occur in three ways: by direct contact with unsterile material on hands, dressings, instruments *et cetera*; secondly, by droplet infection; and, thirdly, by dust from the air.

In regard to the first, the bacteriologist is usually not directly responsible, the use of proper aseptic precautions and preparation of dressings being a matter of discipline for the surgeon in charge of the patient. Nevertheless, in the large proportion of burns the use of saline baths and the frequent early use of skin grafts are especially important to the Royal Australian Air Force bacteriologist.

The beneficial results of saline baths are largely due to the mechanical washing of débris from the wound, and there is little doubt that it proves extremely satisfactory. From the bacteriological point of view it is not so satisfactory since contamination can so easily occur. This may be due to

faulty preparation of the saline solution. In one hospital it was found that the crude salt was grossly contaminated with *Bacillus subtilis* and that this was causing a heavy pollution of the saline solution as it issued into the bath. Similarly, as the result of repeated bacterial examinations, it was found that a rubber feed pipe to the bath had become infected with *Staphylococcus aureus* and this was keeping up the infection of all those who used the bath. Surprisingly enough, the sterilization of the bath itself, providing that the enamel of the bath was intact everywhere and had a highly polished surface, was found to be a comparatively easy matter. An experiment to show this point was made.

Two baths were taken, one treated with lysol solution 1 in 20 and the other rubbed without the use of antiseptic. Both were swabbed and found to be completely sterile, aerobically and anaerobically. The baths were then filled with water from the taps and allowed to stand for five minutes. The water was then collected and put up for a routine bacterial investigation of water sample. Neither contained any organisms of the coliform group or of a pathogenic nature.

The speed with which bacteria are spread by these baths is shown by the fact that samples of water taken after the patient had been immersed for five minutes had a coliform count of over 1,700 organisms. It can be readily seen, therefore, that if multiple wounds are present and the baths are used, the wounds tend to become infected by the same organisms. This, of course, is extremely distressing if the organisms are of a pathogenic variety, and is of extra importance when it is realized that the majority of these patients will require early skin grafting.

For skin grafting, as has already been stated earlier, it is essential that the wound should be almost sterile. The presence of such organisms as β-hæmolytic streptococcus, *Staphylococcus aureus, Bacillus subtilis, Bacillus coli, Bacillus pyocyaneus* and to a lesser extent diphtheroids and *Staphylococcus albus* are detrimental to thorough taking of skin grafts. Staphylococci are sometimes extremely troublesome to deal with. The use of the coagulase test certainly helps to determine pathogenic strains. It has been found that "coagulase negative" types may be largely disregarded for skin grafts if they are not in large numbers.

Skin grafts do not "take" in the presence of many of the above organisms, but it is interesting to note that the appearance of wounds is extremely deceiving, and it has been frequently found that a healthy looking wound does not mean that it is free from any of these organisms. At the same time the presence of such organisms does not always mean that the wounds will not heal. Nevertheless, routine swabbing of wounds before skin grafts is essential.

The spread of infection by the droplet method has of course been stressed by a number of writers. Once again this is of considerable importance where burns are concerned, and in routine surgical ward work for the reasons given above. The control of such infections appears to fall largely upon the bacteriologist, although precautions should be taken similar to those practised in maternity wards or in modern operating theatres.

The routine swabbing of all patients and medical attendants for the presence of pathogenic bacteria on entry to the ward appears to be imperative.

In actual practice this usually consists in detecting those persons who are carriers of β-hæmolytic streptococci, since these organisms are responsible for the majority of such outbreaks. It is essential that proper means of identifying streptococci should be available. The use of soluble hæmolysin has proved invaluable for the determination of the truly hæmolytic streptococcus. Occasionally it is necessary to perform group precipitin tests, but

by the time these tests have been performed the damage has already been done. It is therefore wiser to isolate all carriers of doubtful streptococci until the strains prove harmless.

The typing of streptococci need not be performed in the vast majority of cases, since organisms showing positive soluble hæmolysin must be considered dangerous. It is only in the case of persistent carriers that typing is of value.

In this connexion it has been found that medical attendants are extremely loath to report colds or sore throats, since they frequently consider themselves not to be a danger. In actual practice it is found that many of these so-called colds are mild streptococcal infections, and it has been the custom now to isolate all those who are affected until a swabbing has proved them "safe".

The use of masks must be considered an absolute routine procedure in the dressing of wounds or in the preparation of instruments and dressings.

The spread of infection by dust, although not at the moment considered of such importance as that of droplet infection, has been commented on by numerous writers. For this reason it is essential that brushing of carpets or floors or any procedure which may create a dust must be abolished. The use of oils, such as spindle wood oil *et cetera*, has been advocated and these certainly appear to lessen the spread of infection. It is advisable that no dressings should be done until at least half an hour after the cleansing of the floors of the wards.

In conclusion, as has been so aptly put in the Medical Research Council memorandum on hospital infection, wounds should be treated with the same care as the bacteriologist treats his culture media.

REFERENCES.

(1) E. J. Radley Smith: "Tetanus in a London Sector in Two Years of War", *Proceedings of the Royal Society of Medicine*, Volume xxxv, March, 1942, page 240.

(2) R. Watson Jones: "Treatment of Fractures and Fracture Dislocations of Spine", *Journal of Bone and Joint Surgery*, Volume xvi, January, 1934, page 30.

(3) A. H. McIndoe: *Proceedings of the Royal Society of Medicine*, Volume xxxiv, November, 1940, page 56.

ORTHOPTICS IN THE FIELD.[1]

By J. Bruce Hamilton,
Major, Australian Army Medical Corps, Australian Imperial Force.

The war will soon be in its fifth year, and there is not the slightest doubt that both the civilian at home and the soldier in the field are reacting to the irksome restrictions and changed conditions which total war produces.

Hurst, in his recent work on medical diseases of war (1940), writes:

> An error of refraction which has previously caused no trouble may give rise to severe headaches in a man exhausted as a result of active service, or in a man who has been concussed by the explosion of a shell.

My recent experience is that exhaustion or concussion will not only make manifest refractive errors, but also latent muscular errors, and will produce such a lowering of convergence response that asthenopia and cephalalgia can usually be expected.

Our present illumination difficulties in the Middle East require immediate attention. By day, especially in the desert areas, the glare from the sand is almost blinding, yet little is done to protect the eyes of soldiers from 10,000 to 20,000 foot candles of light. By night, owing to black-out restrictions, these same men are expected to relax at cards or write letters with one hurricane lamp shared between ten or twelve individuals, so that the best illumination each can expect is about 0·25 foot candle; or they are detailed to make long reconnaissances by starlight. For generations their ancestors have not experienced, or have been protected from, glare, while indoors their artificial illumination has been steadily improving. Suddenly our soldiers have been thrown back on their night senses which have been dormant for many generations. Thus we have: (*a*) mental fatigue after three years of total war, (*b*) ocular fatigue due to excessive or deficient illumination. These two together should suffice to make manifest as headaches a previously innocuous refractive error. They do more than this, for they make manifest as asthenopia a previously innocuous latent muscular imbalance or produce a primary one.

Culpin, in "Modern Trends in Ophthalmology" (1940), writes:

> The development of orthoptic treatment is a practical step towards a psychological method of attack when dealing with asthenopias.

However, I am now firmly of the opinion that most of the soldiers to whom I am about to refer are not suffering from psychological conditions (although I have seen many following severe reaction after an engagement), but from true fatigue phenomena.

Statistics.

So convinced was I from the beginning of my army service that, besides refractive errors, muscle errors would be an important factor, that I decided that every soldier suffering from asthenopia or inflammatory eye disease should be submitted to a Maddox wing and rod examination, a *punctum proximum* estimation, and a subjective and objective convergence test. The revelation is worthy of note. Of 3,285 Australian patients submitted to these tests, 599 showed some major or minor ocular imbalance, as shown in Table I. This gives a case incidence of 18·2%.

[1] Accepted for publication on March 9, 1943.

TABLE I.

Condition.	Number of Cases.
Accommodation paralysis	7
Convergence excess	14
Convergence insufficiency	147
Divergence excess	1
Divergence insufficiency	76
Esophoria	149
Esotropia	37
Exophoria	114
Exotropia	25
Overaction of inferior oblique muscle	14
Overaction of superior oblique muscle ..	1
Paralysis of external ocular muscles	14
Total	599

It has been suggested to me that I am wasting my time recording muscle errors in members of the forces; but I am not for one moment suggesting that each and every one of these men needed treatment. What I do endeavour to point out is that every soldier with asthenopia who has no appreciable refractive error under mydriatic, has most possibly a measurable muscle imbalance which is easily correctable with orthoptics of a very simple type.

INSTRUMENTS.

My field armamentarium of orthoptic instruments, while primitive, is on the whole very effective. It consists of the following:

Six home-made diploscopes, of which two have "DOG" on transparent screens. These transparent screens are a most useful innovation.

Six talcs of cleaned X-ray film in a cardboard frame.

Two "Victory" rules.

Six wooden meat skewers with points coloured with red ink.

Two Javal grids for bar reading.

One Pigeon-Cantonnet stereoscope, with pictures—all home-made.

One Remy separator with slides.

One home-made Maddox wing and one Maddox rod with spotlight.

Two occluders, one box of dominoes, one "Ludo" set, and a pack of playing cards, for amblyopic stimulation.

The patient's own index fingers.

Now let me explain briefly the above instruments and point out their individual advantages.

1. The diploscopes and their use are described fully in Lyle and Jackson's "Practical Orthoptics" (1940), and I employ them chiefly for the convergence insufficiencies, the exophorias and the accommodation convergence imbalances. I also found that by using a piece of cleaned X-ray film with "DOG" painted on it, the instrument could be used with great effect with esophorias by relaxation on a very distant object.

2. The talcs are primarily important in relaxing for esophoria or divergence insufficiency; although in one case, with a superior oblique paralysis, I found a talc of the greatest help in reducing the diplopia.

3. The "Victory" rule, invented by Miss Gilchrist, of Hobart, is most helpful when starting a patient with convergence insufficiency or exophoria on his way. It is simply a lath of wood two feet long with a line painted down the centre. The patient gazes at the far end of the line, touches this with the skewer and gradually draws the skewer along the line towards his face. Figure I explains the manœuvre diagrammatically.

4. The wooden meat skewers, besides being useful in the "Victory" rule, are invaluable for involuntary convergence and for physiological diplopia, both crossed and uncrossed. May I here stress the great importance of physiological diplopia as an exercise.

5. The Javal grids for bar reading need no explanation. They were made for me by a member of the Royal Engineers staff.

6. The Pigeon-Cantonnet stereoscope, made from the sides of a kerosene case and a hand mirror, did not prove very helpful, and I cannot say that it is very necessary. Further, the drawing of the necessary slides is somewhat difficult and these seem to be coveted by all patients.

7. A Remy separator for amblyopic patients is definitely useful. I have been able to stimulate so successfully the vision in the amblyopic eye of a "B" class man that he was reclassified "A" class with ease.

8. The Maddox wing was made by one of the patients from tin and thin wood, and is very helpful for relaxation and convergence in the final recovery of patients with esophoria and exophoria respectively. The spotlight for the rod can easily be made from a small biscuit tin.

9. The occluders, which are simple monocular eye shields, *plus* the dominoes, "Ludo" and playing cards, kept soldiers amused for hours and were a decided help in curing *amblyopia ex anopsia* and functional amblyopia.

10. The patient's own index fingers for involuntary and especially voluntary convergence are invaluable. They can even be used for physiological diplopia, but have disadvantages in this exercise.

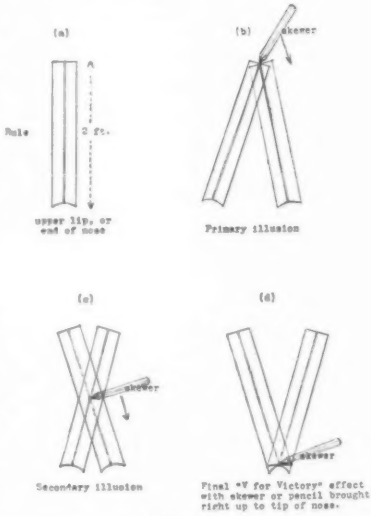

FIGURE I.

RESULTS.

I have not mentioned the 'tropias in my results, for I seldom attempted to treat them owing to the time problem; but when this has not been paramount I have found an occasional exotropia respond in a most stimulating way to the same procedures as the exophorias. Esotropias are quite out of the question of treatment in the field.

The concluding section of this paper is devoted to the results obtained by these primitive methods. Of the 599 subjects with muscle abnormalities, 125 were submitted to orthoptics. The remainder were passed over either because their condition was beyond our sphere, or we felt that the correction of their refractive error would be more advantageous, or because of lack of time.

Table II gives a broad outline of what was attempted and what was accomplished. In all, 125 men were treated in full. The treatment of others was started, but they were unable to complete the treatment for various reasons. I did not include those who had only one or two treatments and then discontinued; but I did include those who had three or more treatments and still were not cured. In the field one is influenced by troop movements, transport difficulties and, to a lesser extent, by the unwillingness of some men to avail themselves of specialized treatment.

The low average daily attendance is due to the fact that each attendance was a full day's session from 0900 hours to 1630 hours, with an interval of an hour for lunch. This was repeated daily till a cure was effected. This method, I think, was on the whole a great advantage, and I am sure was a great improvement on the half-hour treatment thrice a week which pertains in private practice throughout the Empire.

TABLE II.

Disease.	Number of Patients Completely Treated.	Average Daily Attendance.	Percentage Cured.
Convergence excess	2	3·5	100
Convergence insufficiency ..	65	5·5	82
Divergence insufficiency ..	3	6·0	67
Esophoria	15	8·5	67
Exophoria	33	6·0	97
Functional amblyopia	3	6·0	67
Amblyopia ex anopsia	4	11·0	75
Total	125	6·5	79

The greater percentage of cures in exophoria (97) than in the convergence insufficiencies (82·5) is probably due to the fact that some of the latter are psychological in nature. I suggest that on a rough estimation 50% of convergence insufficiencies were psychological. On the basis of the results of the functional amblyopias in which 67% were cured by orthoptics, then: of 50% non-functional convergence insufficiencies, 100% should be cured; of 50% functional convergence insufficiencies 67% should be cured; or an equal proportion of both the above should give 83·5% cured.

Our convergence insufficiency results were actually 82%, which is a very close figure to the above theoretical estimation. I feel that these insufficiencies of functional origin are, nevertheless, just as worthy of treatment as the non-functional insufficiencies, but are not so productive of results.

This brings me to the three functional amblyopias treated with orthoptics. I know this was prostituting the science; but all other methods had failed to relieve the disability. In all, I saw 31 patients with functional amblyopia among 3,285 Australian patients examined, so I cannot be accused of gross abuse.

Of the 113 patients with *amblyopia ex anopsia* seen, only four were exercised and of these three were cured. One patient, to prevent being boarded "B" class, after 22 visits, improved his vision from less than $^{6}/_{60}$ to $^{6}/_{9}$. His age was twenty-three years. My feeling is that, especially in the *amblyopias ex anopsia* accompanying exotropia, great improvement can be obtained in willing subjects up to thirty years of age. I have had two similar patients in private practice, who by concentration improved a divergent amblyopic vision of $^{6}/_{60}$ to $^{6}/_{9}$. Both were over twenty-five years of age. This is a point worth recording, and revises our older notion that all lazy eyes in patients over ten years of age are beyond recall to useful vision.

I think I need hardly point out that these results, from the simplest of treatment and with the simplest of instruments, were most encouraging. I must, however, emphasize that treatment was carried out only when refraction exhibited no error or when the correction of refractive errors did not cure the muscular imbalance and left the patient's symptoms unrelieved.

ACKNOWLEDGEMENTS.

I wish to thank Staff Sergeant M. Lee-Bernstein, Sergeant K. H. MacFarlane and Private G. Petty for their continued help, both with the treatments and the compiling of these statistics. To Colonel W. Summons, O.B.E., V.D., Commanding Officer of the Australian General Hospital, I offer my appreciation for allowing me to publish another paper.

BIBLIOGRAPHY.

M. Culpin (1940): "Modern Trends in Ophthalmology" (London), page 50.

A. H. Hurst (1940): "Medical Diseases of War" (London), page 89.

K. Lyle and S. Jackson (1940): "Practical Orthoptics in the Treatment of Squint" (London), page 9.

THE USE OF SPINAL ANÆSTHESIA IN GENERAL SURGICAL PRACTICE.[1]

By Arthur E. Brown,
Colac, Victoria.

In the forty odd years since Barker introduced into English practice from Germany the use of "Stovaine" by spinal injection, this type of anæsthesia (which word, though strictly less correct than analgesia, is in general use and may for convenience be retained) has undergone many vicissitudes. It had a very hard struggle for acceptance; and that its use has finally emerged into a standard procedure whose great value is generally recognized, is due as much to the breaking down of ill-founded prejudices as it is to improvements in the anæsthetic agent and in the technique of its use. Many men, of whom I am one, have gone through a stage of initial enthusiasm and a phase of exasperation at its uncertainties and its irresponsible behaviour, and have reached a stage in which it is a safe and delightful aid to surgery. I now use it as a routine procedure in 50% of all my operations. Of the other 50%, 16% are performed with local infiltration methods, and 34% of the whole with ether given by the open method. General ether anæsthesia is reserved for young children, highly nervous patients, those "immediate" operations in which there is not time for a proper premedication of the patient, Cæsarean sections in which the premedication used may be expected to be harmful to the baby, and for those regions of the body which are regarded as being outside the reach of spinal anæsthesia. The last mentioned in my practice include operations on the breast.

The principal practical conditions which have in the past militated against the general acceptance of spinal anæsthesia have been, apart from an intrinsic prejudice against the procedure itself: (*a*) uncertainty as to the level and duration of the anæsthesia to be expected; (*b*) fear of a lesion of the central nervous system following its use; (*c*) fear of the fall of blood pressure during the operation; and (*d*) dislike of the headache and backache of which patients often complained during their convalescence. All these have now been to a large extent eliminated.

The uncertainty as to level of the anæsthesia obtained and its duration was most noticeable during that period when "Novocain" was the standard drug used. With the earlier used "Stovaine"-glucose solutions this uncertainty was not nearly so much in evidence; but the relative non-toxicity of the "Novocain" solutions gave them an advantage which made them widely preferred. During the years in which I used "Novocain" there were many cases of excellent anæsthesia which were all that could be desired. But there was an erratic character about its behaviour which was at times very disconcerting, and which lent an atmosphere of uncertainty to any operation proposed. Though the drug was injected at the same level, in the same amount and at the same rate, the level of anæsthesia might vary anywhere between the pubes and the nipple line, and its duration anywhere between twenty minutes and three-quarters of an hour, rarely longer. Since the substitution of "Percaine" for "Novocain" as the active agent these eccentricities have disappeared. The level of anæsthesia is a stable factor within very narrow margins, on which one can rely; while, except for the exceptionally prolonged

[1] Accepted for publication on April 2, 1943.

procedures, the duration of the anæsthesia is ample and has not to be considered.

The second objection, the fear of untoward sequelæ in the central nervous system, is one which appears to be gradually disappearing with the years as they bring experience. I myself have never met such sequelæ, whether using "Stovaine", "Novocain" or "Percaine". Discussions with other men who use the method freely, serve to strengthen the opinion that this state of affairs is not due merely to my own lucky star, but that the fear of such unhappy events has been greatly exaggerated, and that this fear has unnecessarily retarded the general adoption of this very valuable method. The remaining two aspects of this subject, the much dreaded fall in blood pressure and the "post-spinal" headache, I shall leave for discussion a little later.

The technique at present used is neither original nor peculiar. It has been adopted because of the excellent results its gives and because of its extreme simplicity. In country practice, where there is no surplus of qualified assistants or anæsthetists, this is highly desirable. I have avoided the turning about of the patient after the method of Howard Jones, and also the more complicated endeavours to get "zonal" anæsthesia by means of air or oil replacement techniques. Such instruments as "tiltometers" are not part of the theatre equipment. I do not question the value of these methods, but satisfactory anæsthesia for the vast majority of patients can be obtained without them. After routine skin preparation, the patient is given a hypodermic injection of morphine, one-quarter of a grain, with hyoscine, one one-hundredth of a grain, an hour and a half before the time set for operation. An hour later he receives a second injection of a sixth of a grain of morphine and one one-hundred-and-fiftieth of a grain of hyoscine, the latter injection being given after he has been lifted onto the trolly. His eyes are lightly bandaged, his ears plugged with cotton wool, and he is left screened off on the trolly in the ward until taken to the theatre. When he is lifted onto the table he is made to sit up, and the anæsthetic agent is injected through a small skin wheal of "Novocain" into the third lumbar intervertebral space. If the operation area is below the umbilicus the agent used is 1 in 200 "Percaine" in buffered isobaric solution, of which two cubic centimetres are given. It is diffused by barbotage two or three times, and the patient is immediately laid flat. If the operation area is above the umbilicus, a solution of "Percaine" of lower specific gravity than that of the cerebro-spinal fluid and of 1 in 1,500 strength is used. Twelve cubic centimetres of this are injected into the third lumbar space with the patient sitting upright and at a rate of a little less than one cubic centimetre per second. The patient is held upright for twenty-five measured seconds from the start of the injection and then laid flat. In all cases, before laying the patient down, half a grain of ephedrin is injected through the skin wheal into the erector mass of muscle on one or other side. The spinal injection having been given, the surgeon and his assistant proceed to scrub up in thorough and leisurely fashion, the patient is draped, and the first incision is generally made some fifteen minutes after the injection. This interval is sufficient in nearly all cases to allow of good analgesia and muscular relaxation taking place in the operation area. In those cases in which it is not sufficient, a further period is generally allowed, but usually other measures have to be taken. After the completion of the operation, care is taken to keep the patient as completely at rest as possible. He must of course be lifted from the table to the trolly and from the trolly back to bed, but all is done gently; and once back in bed he is kept in the flat position, which includes low pillows under the head, loins and knees, for twenty-four hours; after this time he is encouraged to move about as much as possible, with due regard to his surgical condition.

That in brief is the whole of the technique. It remains now to discuss it in the light of the principles involved.

The method of premedication is in my opinion vitally important; so much so that in such operations as Cæsarean section in which heavy doses of morphine might be expected to be harmful to the baby, or in the treatment of patients to whom one feels that the heavy drugging might bring adverse effects, I prefer to forgo the very great advantages of spinal and operate with general anæsthesia. For a number of years no suitable method of dulling the patient's sensibility had been worked out and the procedure was omitted. In these days a large number of severe and very disturbing falls in blood pressure occurred. Also the emotional stress to which the patients were subjected was evidently disagreeable to them, and I had to cast about for some means of avoiding it. For some years I gave large doses (fifteen grains) of "Luminal", but I found that only partly satisfactory. I never saw any harmful effect from the dose, but the patient's consciousness was not sufficiently dulled. In fact, there was very little apparent difference in effect discernible whether one gave fifteen grains or five. The apparent advantages of morphine and hyoscine in effective doses were for a long while outweighed by the fear of the restlessness and intractability which are so often shown by patients under the influence of hyoscine. Having, however, observed cases in which these drugs were used freely by other surgeons, I turned to them, and for a number of years now have used them exclusively as a preliminary to both spinal and local anæsthesia. The dosage given is standard. It is not often exceeded, though in selected cases less than that stated is given. The restlessness, though it sometimes is a nuisance when using local anæsthesia, has not proved serious in the use of spinal anæsthesia, for with the flaccidity which follows the spinal injection the lower limbs take no part in it and it is limited to muttering and some movements of the upper limbs which do not seriously interfere with the operator, even in those cases in which they occur. The great and manifest advantage of this method of premedication is an almost complete dissociation of the patient from his surroundings, and the lack of all unpleasant memory of the ordeal. It has the great advantage over the rectal-basal and intravenously administered barbiturates, in that the patient can still cooperate to the extent of being made to sit up for the spinal injection. Its disadvantages lie in the facts that it often causes post-operative vomiting and that in some prostatic conditions particularly it depresses the urinary output to quite a striking extent for a day or two. It is, however, in spite of these disadvantages, in my opinion, quite the best premedicative routine for spinal anæsthesia at present at our disposal and for the great majority of cases is very satisfactory indeed.

The absence of all unnecessary movement of the patient I consider important. On the operating table it helps to keep the patient dissociated, and in the post-operative period the period of rest in the flat position has, I believe, played a very large part in the elimination of "post-spinal" headache and backache. It was the custom here to maintain this flat position for the first thirty-six hours after operation. To the patients, however, the maintenance of strict recumbency during the whole of the second post-operative day was very irksome, and as it ran contrary to the desire to get the patient into a condition of muscular activity as early as possible, the period was shortened to twenty-four hours. It is my impression that the incidence of headache and backache has not been thereby increased, but the position is still being watched.

I have doubts as to whether full weight has been generally given to the psychological and emotional side of the question in discussions on spinal anæsthesia. There is an undoubted widespread repugnance to the procedure

on the passive side and of purely emotional origin. I am inclined to think that most surgeons, even after being well conversant with all the advantages of the method from the surgical point of view, and well knowing too the freedom from trouble and from unpleasant memories which the patients enjoy, would still find it necessary to make a conscious effort to overcome this repugnance before accepting the spinal method of anæsthesia in an operation to be performed on themselves. If to this repugnance is added the emotional stress caused by the fear of operation generally and by the series of professional preparations leading up to it, one can well believe that this condition of emotional tension would be qualified to produce definite effects during the operation. In my opinion these effects are evidenced in two main ways. One is by the fall in blood pressure. In a previous paper on this subject I stated my conviction that vasodilatation, particularly in the splanchnic area, could not be called upon to account for this fall; and I am not unduly impressed by the suggestions that similar vasodilatation more peripherally can be substituted for it. It is true that the widespread paralysis of motor and sensory function in the area of the body affected by the spinal agent may well cause a certain amount of depression of the blood pressure, in the same way in which one may notice a difference in the diastolic and systolic pressures in the same person if they are taken during periods of mental and physical excitement or of mental and physical relaxation. But it appears to me to be a very strong probability that the major fall—the fall which used so to alarm us, with pallor, sweating, sighing respiration and sometimes vomiting—is an emotional effect precisely similar to the fainting attack produced in many people by the mere approach of the hypodermic needle. I have felt supported in this opinion by the fact that since I have been dissociating the patient from his surroundings and using every effort to eliminate this nervous stress, I have never seen a single case of the severe circulatory collapse such as used to be only too frequent before that time. In fact I have now deliberately ceased to record blood pressures during the operation. The technique of dissociation is carried out as thoroughly as possible. Every unnecessary stimulus to the patient is avoided. Such interference with his relaxation as repeated sphygmomanometer readings or the testing for the upper limits of the anæsthesia, though they are in themselves useful, have been abandoned. The theatre staff has been trained to a technique of strict silence, and the same rule of silence is observed by the surgeon as far as is practicable from the time of the patient's entry into the theatre until he leaves it. During the operation the need for any instrument is indicated by well established manual signs, and only the irreducible minimum of talking takes place. Quite apart from the fact that this technique assists the masks on the faces of the staff to maintain their function of filtration, I believe it has been worth while on general grounds.

In addition to playing a part in the production of the dreaded blood pressure fall, I believe that emotional tension is a prominent factor in the development of that resistance to the action of sedative and anæsthetic drugs which these patients sometimes exhibit. A good deal has now been written about the phenomenon referred to by the rather dreadful name of "rhachi-resistance"; and various attempts have been made to explain why in some cases in which the anæsthetic agent has without question been deposited inside the spinal theca and has mixed with the cerebro-spinal fluid, the anæsthetic effect fails in part or entirely (though seldom the latter) to develop. I should not like to be as dogmatic in ascribing this failure to emotional stress as I have been in regard to the fall in blood pressure; but my experience suggests very strongly that stress does play a large part in its causation. It is noticeable that the patients who exhibit resistance to the

action of the "Percaine" are in the main the same patients who exhibit a similar resistance to the sedative action of the hyoscine and morphine and who, instead of lying drowsily on the table, keep up a constant flow of nervous comments to the effect that they are not asleep yet. This correspondence is not exact, but it is sufficiently nearly so to be striking. When the time comes to commence the operation they give evidence of feeling the towel clips pinching their skin and usually the lower equally with the upper pair. They wince and protest at the skin incision. It is obvious that they do not feel anything like the full sensation of a cut in the skin, but their nervous tension increases and it becomes difficult to continue with the operation. In nearly all these patient a little ether on a mask, not nearly enough to bring them to the struggling stage, or half a gramme of "Evipan" into the basilic vein, will relax the nervous tension entirely and permit the drugs previously administered to exert their normal effect, so that the remainder of the operation proceeds as it should. In many of these people there is evidence of failure of motor block equally with sensory. They move their legs and feet, the abdominal reflexes remain active, and the muscles of the abdominal wall fail to relax. I do not pretend to give a pharmacological or physiological explanation of this phenomenon; but it is my experience that this failure in motor block is remedied in the same manner as is the failure in sensory loss.

As a case in point I may quote the case of a lady of middle age who was given a spinal injection of "Percaine" for the performance of amputation of her cervix. She was given a hypodermic injection of a quarter of a grain of morphine and one one-hundredth of a grain of hyoscine at 8 a.m., followed by a similar injection of one-sixth of a grain of morphine and one one-hundred-and-fiftieth of a grain of hyoscine at 9 a.m. She was wide awake on arrival at the theatre and nervously and repeatedly demanding the removal of her eye bandage. Two cubic centimetres of 0·5% isotonic "Percaine" were given into the theca at 9.45 a.m., and she was fairly well relaxed when she was put up in the stirrups at 10 a.m. She was still apprehensive, and light pinching of her labia caused her to flinch and kick against the stirrups with her feet. Light short administration of ethyl chloride on an open mask immediately banished the reflexes from the perineal stimulation, and the operation was conducted thereafter in perfect peace. She awoke later in the day with no memory of having been to the operating theatre at all.

There is an obvious explanation in that sufficient time had not been allowed for the intraspinal reagent to exert its full effect. I do not find this explanation satisfying to me, for I have often waited a considerable extra time in the hope of relaxation occurring, but in vain; whereas the breaking down of the nervous strain is in almost all cases immediate in its effect. I do not want to be too dogmatic about this, and I am not competent to explain it scientifically; but my experience has led me to form the opinion that nervous stress plays a considerable part in this phenomenon of resistance to drug action.

The problem of headache and backache following spinal anæsthesia has not yet been solved, in that there are a few people who do suffer some degree, generally minor, of "sitting up" headache after it. I have deferred to the general opinion that a very narrow bore needle with a short bevel should be used as one means of combating this very troublesome complication. But it is difficult to reconcile this opinion with the common absence of such headache and backache following the ordinary diagnostic lumbar puncture in which these precautions are relatively seldom taken. If the bore and bevel of the needle are important factors in the production of headache and backache after spinal anæsthesia, they should surely be equally operative in producing similar symptoms after lumbar puncture, but they do not do so. Such symptoms may of course be masked to some extent by the conditions for which diagnostic lumbar puncture is commonly done. But the heavy aching head which has occurred so frequently after spinal anæsthesia when the

patient sits up or stands, and which persists for weeks or months, is surely striking enough to have gained attention if it occurred in anything like the same proportion of cases. It appears to me that the activating cause must lie in the injected agent rather than in the technique of the injection; and all one can say is that the true cause is so far unknown and so far has hardly been seriously investigated. Fortunately the headache is now far rarer than it formerly was. The factors which, in my practice at any rate, might have operated in producing this improvement are three. One is the use of the better type of needle, a second is the change from "Novocain" to "Percaine", and the third is the adoption of the flat recumbent position by the patient for a relatively prolonged period. I am unable to think of any others. The influence of the technique of the injection I have already discussed. Of the effect of the change in the injected fluid I am not competent to judge, but I know of no evidence that the general adoption of "Percaine" has abolished the headaches. Certainly as far as the volume of fluid and the strength of the solution injected are concerned, there is no apparent difference in headache incidence whether two cubic centimetres of 1 in 200 or twelve cubic centimetres of 1 in 1,500 "Percaine" are used. Many surgeons of course use much greater volumes of the weaker solution than twelve cubic centimetres and this practice has not been followed by any reported increase in the number of patients suffering post-operative headache.

On the other hand, my experience does lead me to conclude that the maintenance of the patient in recumbent immobility after the operation has definitely been a factor in reducing headache. One comes to that conclusion rather reluctantly in the absence of any satisfactorily worked out rationale for such an apparently empirical procedure. But the worst such headache I have ever seen, and incidentally the only severe one I have seen in the last few years, followed a spinal anæsthetic given elsewhere for a cystoscopy.

On the afternoon of the same day the patient, a young man, got out of bed to reach a urinal rather than ask for help, and he developed a most severe and intractable headache which persisted for some four months.

In the absence of any real knowledge of the cause of the headache and of the mode of action of the remedy, the determination of the optimum length of the recumbent period is very much a matter of trial and error. It is evident that the shorter it can be made, the better both for the patient's comfort and for the restoration of normal circulatory conditions. It is not my impression that headache and backache are any more in evidence or any more severe since this period was reduced from thirty-six to twenty-four hours. Below that I am hesitant to come, having in mind the occasional distressing case characterized by weeks of headache which used to be met with before recumbency was adopted as a routine nursing measure.

This routine is relaxed only in the type of patient in whom one has reason to expect grave pulmonary complications. There are always some of these in whom the chance of headache should be taken as a lesser risk than the prospect of pulmonary collapse or pneumonia. They form a very small percentage of the total patients operated upon, for it can be said with definiteness that the increasing use of spinal anæsthesia, even with the heavy morphinization which accompanies it, has not brought any increase in the incidence of chest complications. The elderly bronchitic prostatic patient tolerates the procedure astonishingly well, especially if given frequent inhalations of carbon dioxide or "Carbogen" during his recumbent period. Their vital processes may be depressed, as is shown by the extremely small quantities of urine which some of them pass in their first two post-operative days, but this is due to the premedication rather than to the spinal injection, since it follows these premedicative drugs equally when the bladder is opened

under local anæsthetic or when the prostate is removed under spinal anæsthesia. This factor, though disturbing when met with, can be avoided by lessening the dosage of the premedicative drugs, and has never given more than temporary inconvenience. It would, however, weigh in my mind more heavily than would the fear of pulmonary complications in assessing the risk of spinal anæsthesia in this type of case. Actually I have never seen in either of them any valid reason to deflect me from using the spinal method.

In addition to the above-mentioned pulmonary complications, other changes of a circulatory nature may of course be expected when to the ordinary surgical trauma is added heavy morphinization and enforced immobility. The gravest of these is pulmonary embolism. One would imagine, *prima facie,* that the conditions surrounding the use of spinal anæsthesia would lead to an absolute increase of this distressing sequela. The morphinization, the paralysis of the lower half of the body, the prolonged immobility following the operation, all would seem to act together in creating the ideal conditions for the development of venous thrombosis and embolism. I am happy to say that I have not found this to be the case. In a period which covers the performance of some 1,800 major operations under general, local and spinal anæsthesia, I can count five fatal cases of pulmonary embolism. Of these, two followed operations performed with spinal anæsthesia (a hysterectomy and a colpo-perineorrhaphy) and three followed operations performed under general ether (one simple cystotomy and two prostatectomies). In addition I have to record another fatal case from the same cause following the reduction of a simple fracture of both bones of the lower limb, the reduction being carried out with ether anæsthesia. In submitting these figures I am well aware that one swallow does not make a summer, but it is necessary also to bear in mind that it is precisely in those cases in which pulmonary embolism has shown itself most likely to occur that "Percaine" has supplanted ether almost entirely as the anæsthetic agent in recent years. And, with this fact in mind, I think I can say with some certainty that the increasing spinal use of "Percaine" has not brought to the patients an increased risk of pulmonary embolism. And apart from fatal cases of pulmonary embolism I have not seen any increased incidence of venous thrombosis in any recognizable form, nor of pulmonary embolism of a minor non-fatal type, although a few of these latter have been observed in the maternity wards of the hospital where spinal anæsthesia is never used.

In general, then, I would say that the use of spinal anæsthesia over the years has proved a very decided boon in my surgical practice. The number of cases in which, for one reason or another, its results fall short of what is aimed at, is steadily diminishing. And in those in which it does achieve its full object, operating is a surgical delight to the operator, and involves no unpleasant ordeal or memory to the patient. The more recent extension of its use to the regions above the waist has been equally satisfactory, and the dangers of the administration do not seem to have increased proportionately. There does not seem therefore to be any valid reason why every surgeon should not familiarize himself with its technique, especially in these days of medical manpower shortage. In metropolitan hospitals, where the use of specialist anæsthetists is a routine, and where training in the giving of anæsthetics is carried out, the surgeon naturally feels that the operative area puts enough responsibility on him without his having to watch the patient's general condition as well. In the country conditions are very different. Even in normal times it is a gain that as few doctors as possible should be tied up in one piece of work; and in these days of shortage it has made just the difference in my own sphere of activity between getting through the work and failing to do so. I find it no disadvantage to give the injection myself and

then to continue with the operation, relying on the judgment of an experienced nurse to warn me of any change in the patient's condition. Even in the bad old days when severe falls in blood pressure were more frequent than they are now, I found this arrangement satisfactory. A few minutes' cessation of the surgical manœuvres while the head of the table was steeply lowered was in all cases enough to restore the patient's circulation and to permit me to proceed with all confidence. I have not had to do this now for the past six or seven years. This deliberate statement may seem to sound a note of danger in the ears of surgeons accustomed to working with full operating teams. In teaching hospitals, and for the purpose especially of the study and development of new anæsthetic techniques, the full team is in every way desirable. But with the present pressure on medical personnel I think it only right for me to state as a result of twenty-five years' experience that the intelligent use of spinal anæsthesia in the way I have described is safe, pleasant both for the patient and the surgeon, and will very greatly ease the problem of overwork in the medical sphere.

Surgical Technique.

THE INTRODUCTION OF THE INTERCOSTAL TUBE: AN IMPROVED METHOD.[1]

By Russell N. Howard,
Major, Australian Army Medical Corps, Australian Imperial Force.

Intercostal drainage has an established place in the treatment of *empyema thoracis*. One of the factors most conducive to its success is the selection of the suitable drainage tube. Failure to attend to this point is responsible for much of the trouble encountered by those using the procedure. It is claimed that the type of tube and the method of tube introduction described below combine to give the procedure its maximum efficiency and technical simplicity.

Existing Techniques and Their Defects.

There are two techniques at present in common use.

The first involves the introduction in the pleural cavity, through a large intercostal cannula, of some type of self-retaining rubber catheter stretched on an introducer to diminish its calibre. When the introducer is removed the catheter diminishes in length, increases in calibre and is grasped firmly by the cannula. Therefore it has to be inserted sufficiently far into the pleural cavity to enable the cannula to be withdrawn to the skin surface and the catheter grasped here by forceps while the head of the catheter is left inside the chest; the cannula can then be pulled off the catheter. Thus the catheter on its introducer must invade the pleural cavity for a distance equal to the full thickness of the chest wall *plus* about two inches to allow for the contraction of the rubber and one inch as a margin of error—a total of some four inches. If the empyema is less than four inches in breadth the catheter may penetrate the lung and initiate the formation of a broncho-pleural fistula. Means to avoid this excessive penetration only introduce further difficulties. Again, however much of the self-retaining head of the catheter may be cut away, a certain minimum must be left for stretching purposes, and this, combined with the universal decrease in bore of such catheters in this region, forms a most unfortunate trap for fibrin clots—a grave defect.

The second method consists in simple insertion between the ribs of a rubber tube along a track made by a scalpel without the use of an introducer. This rather immature procedure makes it difficult to use a tube of adequate size and lacks the complete control of the technique about to be described.

From time to time metal tubes have been used, but have now been generally abandoned on account of the pain they cause and their tendency to injure the expanding lung.

An Improved Technique.

The essential elements in this are the intercostal tube and the introducer, which are of the author's own design.

The tube is of rubber and is chosen so that its calibre, thickness of wall and rigidity are compatible with the width of the intercostal space and the amount of negative pressure to which it is likely to be subjected. Considerable thought must be given to its selection. One of the great advantages of this method is that a piece of any tubing selected as suitable can rapidly be transformed into an intercostal tube as follows. One-quarter of an inch from the end of a standard length of the tubing, at opposite ends of one of its diameters, two small holes are made with a cork-borer and this end is then cut so that when stretched, with each hole caught on one of the legs of the introducer slot, the shape is that of a blunt asparagus tip (see Diagrams A and C).

The introducer consists of a rigid cylindrical metal rod twelve inches long and one-sixth of an inch in diameter with slotted end, the slot being one-tenth of an inch wide and one-fifth of an inch deep. The legs of the slot are rounded, expanding at their base, where they meet to form the body of the rod (see Diagram B).

With the aid of "Elastoplast" a sponge rubber pad about two and a half inches by three and a half inches by one-quarter of an inch, perforated at its centre for the passage of the tube, anchors the tube firmly to the chest wall.

[1] Accepted for publication on May 6, 1943.

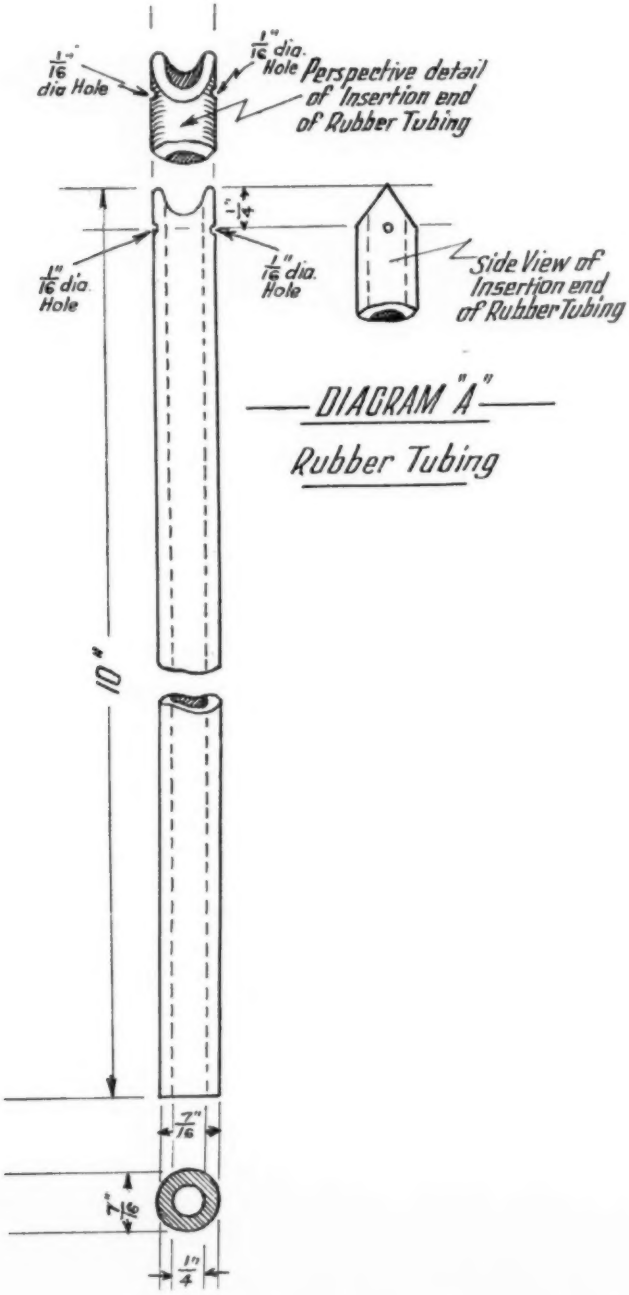
1/16" dia Hole
1/16" dia. Hole
Perspective detail of Insertion end of Rubber Tubing
1/16" dia. Hole
1/16" dia. Hole
Side View of Insertion end of Rubber Tubing
DIAGRAM "A"
Rubber Tubing
10"
7/16"
7/16"
1/4"

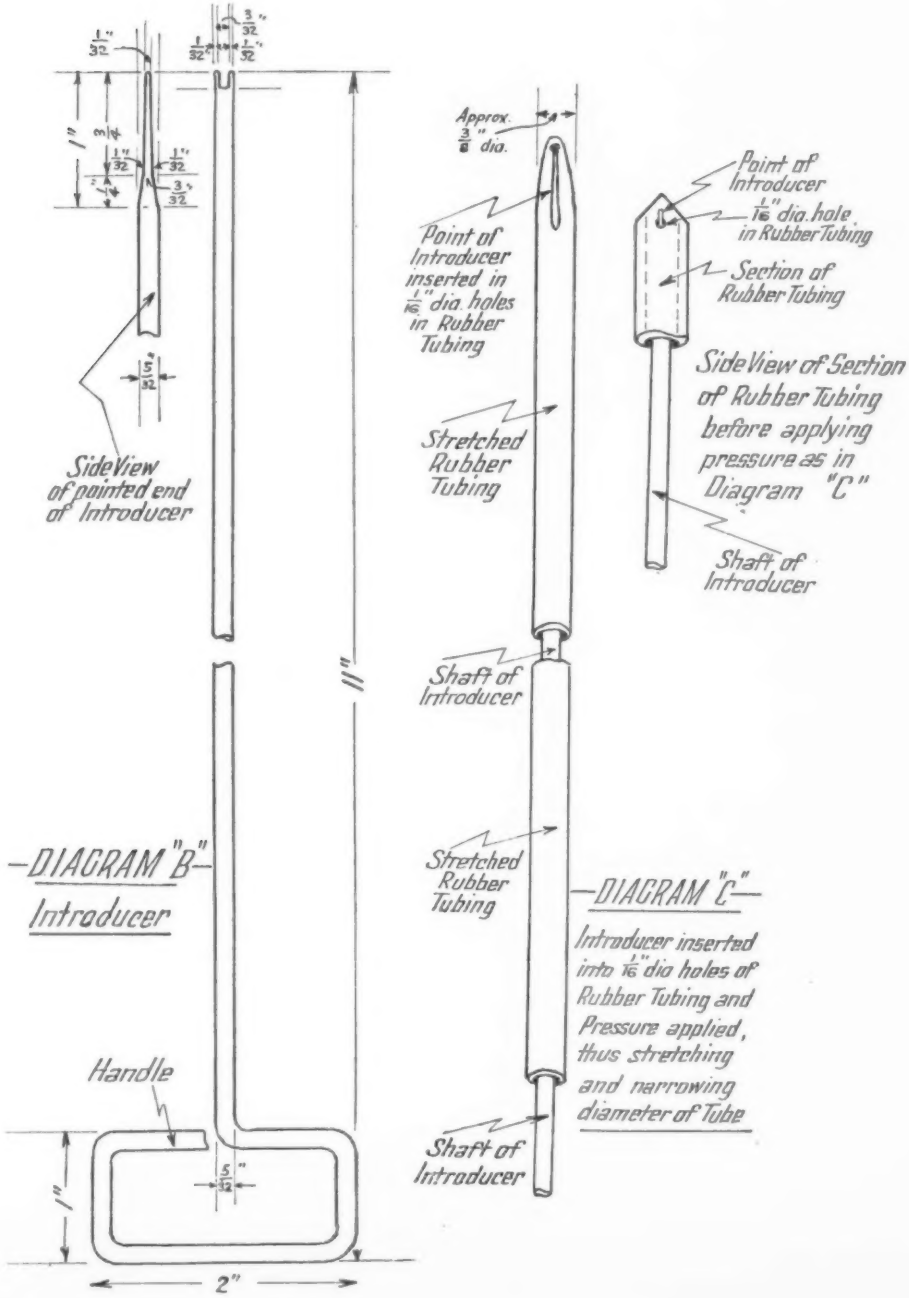

—DIAGRAM "B"—
Introducer

—DIAGRAM "C"—
Introducer inserted into 1/16" dia holes of Rubber Tubing and Pressure applied, thus stretching and narrowing diameter of Tube

The operation is performed on the patient in his bed in the ward. One-quarter of a grain of morphine is administered three-quarters of an hour beforehand. The position in which the patient is placed depends on the proposed site of introduction of the tube. If it be at the "site of election", I prefer him sitting up and leaning forward over a "heart table"—a comfortable and stable position. Local anæsthesia infiltration is now performed as for chest aspiration, but a slightly greater intradermal injection is used and great care is taken to anæsthetize the parietal pleura thoroughly.

The depth of the pus from the skin is now carefully estimated with an exploring needle. This length *plus* one-half of an inch is the length of tube which will be deep to the skin surface (one-half inch projection of the tube into the pleural cavity is desirable). A mark is made with gentian violet on the tube at this distance from its inner end. The introducer is now carefully greased and passed up the tube, its two prongs engaging in the two holes. The sponge rubber pad is drawn on until its inner surface coincides with the gentian violet mark and the tube on the chest side of this is liberally greased with "Vaseline" (especially in the region of the introducer prongs). An incision large enough to accommodate the tube is made in the skin and through it is inserted, just into the pleural cavity, an ordinary intercostal trocar about the size of the tube to be used (this is simply to make a track and could be effected, although less adequately, by passing the scalpel to the required depth). The tube is stretched on the introducer and held clamped by the right hand grasping it at the external surface of the sponge rubber (see Diagram D). With the left hand the trocar is withdrawn and the tube (on the introducer) is immediately pushed down the track until the sponge rubber rests on the skin surface. The introducer is withdrawn immediately—it slips out quite readily—and the tube is clamped with a Spencer Wells forceps to stop entry of air into the chest. The sponge rubber pad is now strapped to the skin and to the tube with "Elastoplast". With careful nursing it will be found that there is no tendency for the tube to pull out.



DIAGRAM "D"
Showing manner of inserting Tube "A"

By the use of this method one obtains:

1. Introduction of the intercostal tube in such a way as to cause no more disturbance to the patient than does a simple chest aspiration.

2. The use of a tube of suitable calibre and thickness of rubber without the disadvantageous "hood" attachment of a self-retaining catheter.

3. Insertion of the tube to the exact level desired without preliminary extensive penetration of pleural cavity (and possibly of lung)—a most important point in the drainage of small collections of pus.

4. Simplicity of apparatus. This is of considerable moment in war surgery where self-retaining catheters cannot always be obtained. The trocar is used simply to give a track and can be dispensed with.

Summary.

The disadvantages of the common methods of introduction of the intercostal tube are pointed out.

An improved technique is described and its advantages are delineated.

Case Reports.

GANGLIONEUROMA OF THE SUPRARENAL GLAND.[1]

By E. S. J. King,
Lieutenant-Colonel, Australian Army Medical Corps.

Diagnosis of ganglioneuroma of the suprarenal gland is usually difficult, and the present case is no exception to the rule. It is recorded partly because of its intrinsic pathological interest, but in addition to emphasize the necessity for repeated critical consideration of all observed phenomena.

Clinical History.

A.A.T., male, aged twenty years, had never had any illnesses of note and had had twelve months' military service when he was admitted to a hospital in the Middle East with a pyrexia of sudden onset. He complained of headache, lassitude and cough. He had a temperature of 100·2° F., a pulse rate of 108 a minute and respiratory rate of 22. Bronchi were audible over the lungs and an enlarged "spleen" extending to the umbilicus was palpated.

Blood examination failed to demonstrate any malarial parasites, but he was noted to have an eosinophilia of 25%. Red blood cells numbered 5,860,000 per cubic millimetre, the hæmoglobin value was 110% and white blood cells numbered 18,400 per cubic millimetre. His fever subsided in two days and his general condition appeared normal. X-ray examination of the abdomen revealed a large homogeneous mass in the left hypochondrium, the left kidney being observed distinct from this. An excretion pyelogram showed normal excretion in both kidneys with normal shaped pelves, though there was some delay in emptying of the left side, "apparently due to pressure of the mass". X-ray examination of the lungs revealed "soft, patchy mottling throughout almost the whole of both lung fields".

Repeated investigations failed to show any evidence of schistosomiasis. However, a course of injections of tartar emetic was given. Three weeks later X-ray examination of the lungs revealed considerable resolution of the mottled areas. Eight weeks after his admission to hospital his general condition was very satisfactory, the enlarged "spleen" was the same size and an eosinophilia of 28% was still present. Ova of *Ascaris lumbricoides* were discovered in the fæces. It was decided to repatriate him.

While returning to Australia, he began to have attacks of stabbing pain in the left hypochondrium extending round to the back and lasting for five minutes. He would have two or three attacks in a day. They were made worse by bending forward and were completely unaffected by meals. Sometimes he had slight regurgitation of food immediately after meals, but he did not vomit and there was no general abdominal pain.

Four months after the onset of original symptoms he was admitted to a base hospital. Blood examination showed the red cells to number 6,300,000 per cubic millimetre; the hæmoglobin value was 115% and the white cells numbered 10,000. The Wassermann test produced no reaction; the result of the hydatid complement fixation test was negative; fragility of the red blood corpuscles was normal. Several examinations for malarial parasites gave negative results.

In addition to the enlarged "spleen" enlarged lymph glands were observed in the axillæ and in both sides of the neck. It was thought that the cervical enlargement was associated with *impetigo contagiosa* of the face. This recovered rapidly with treatment and the glands subsided. An enlarged gland was removed from the left axilla, and this showed considerable endothelial proliferation and some multinucleated cells, but the diagnosis of the condition was uncertain.

Three weeks after the patient's admission to base hospital deep X-ray therapy was given to the mass, a provisional diagnosis of Hodgkin's disease having been made. At this time X-ray examination showed the lung fields to be clear and there was no widening of the mediastinal shadow. After six weeks of X-ray treatment no appreciable change had occurred in the mass. The blood examination showed the red cells to number 4,600,000 per cubic millimetre and the white cells 3,700; the eosinophile cells were 22% of the total white cells. Examination of fæces showed the presence of ova of *Ascaris lumbricoides* and *Trichuris*.

The patient was now reviewed, and the mass, which extended from beneath the left costal margin to the umbilicus, was found not to be in close contact with the

[1] Accepted for publication on January 6, 1943.

abdominal wall laterally and there was some resonance of part of it. Exploration was therefore undertaken.

Operation was begun under local block anæsthesia of 0·5% "Novocain". A right-angled incision was made, the vertical limb being a typical paramedian incision, extending from the xiphoid process to the region of the umbilicus. The other limb extended laterally from the lower end for three inches. The abdomen was opened by passing through the sheath of the *rectus abdominus* and retracting the muscle laterally. The lower portion of the incision was carried through the tendinous inscription and the flat muscles were split lateral to the *linea semilunaris*.

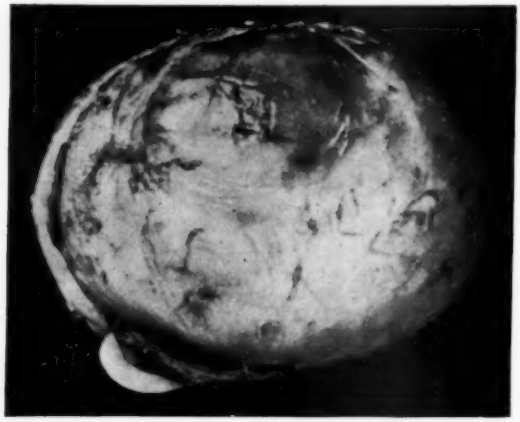

FIGURE I. Photograph of the tumour mass after removal. It is irregularly ovoid, has a smooth surface, and measures seven and a half by six and a half by five inches.

A large mass, having colon in front of it, was found in the retroperitoneal area. An incision was made in the peritoneum lateral to and above the colon, and this was displaced downwards and medially. The tumour was gradually separated, this being done relatively easily once a satisfactory plane of cleavage was found. Its main attachment was at a point just above the body of the pancreas and medial to the upper pole of the kidney. It was removed without incident, though a small amount of ether, administered by inhalation, was required during its removal. Some very large veins were present in the tissues in the neighbourhood, particularly near its point of attachment. A normal spleen and kidney were demonstrated. A drainage tube, around which a remnant of capsule was drawn by a purse-string suture, was inserted.

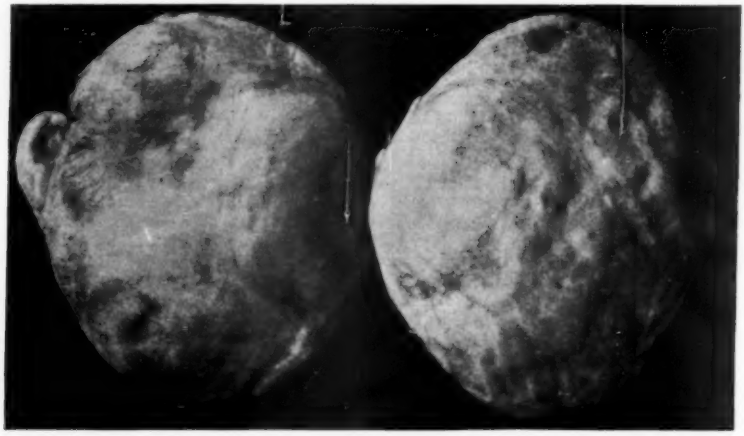

FIGURE II. Photograph of the tumour in cross-section. The surface is of a soft fibrous structure and is homogeneous, except for areas which in the original state were yellowish in colour.

At the end of the operation the pulse rate was 74 a minute. Five hours after the operation there was some vomiting. At first this was blood-stained, but later became clear and greenish in colour. The patient's condition deteriorated: he became pale, sweated and the pulse rate rose to 120 a minute. Glucose saline solution was given intravenously and recovery occurred within twelve hours.

He developed a post-operative basal pneumonia three days after operation, but he recovered satisfactorily from this. Nine days after operation he had, over a period of forty-eight hours, attacks of giant urticaria, which responded to injections of adrenaline. In other respects his convalescence was uneventful. At the time of writing he is very well and has returned to duty.

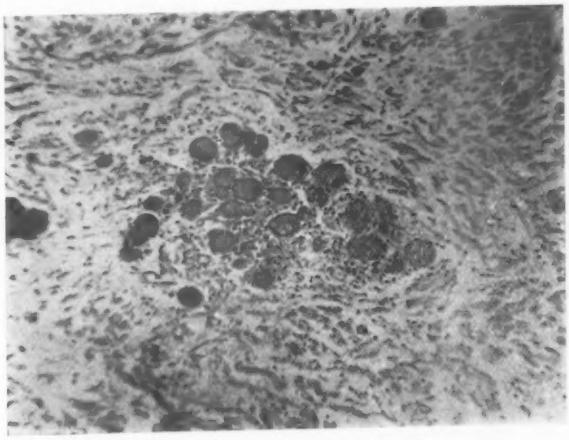

FIGURE III. Photomicrograph showing a group of ganglion cells lying amongst nerve fibres. × 130.

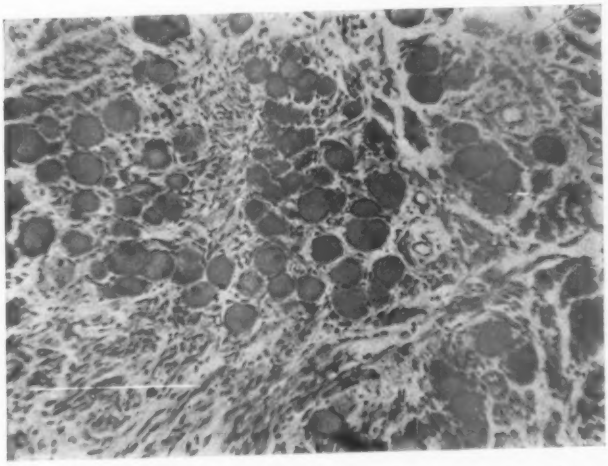

FIGURE IV. Photomicrograph showing a portion of tissue containing many ganglion cells. × 130.

Pathological Examination of the Tumour.

The tumour consisted of an irregularly ovoid mass, measuring seven and a half by six and a half by five inches (Figure I). The surface was smooth; at one area (the hilum) there were some vessels entering it. It felt soft and "semi-fluctuant".

On gross section it was composed of white fibrous tissue which was somewhat gelatinous or mucoid in consistence (Figure II). There were irregular areas of yellowish tissue in patches throughout the cut surface. Tiny calcified spicules were present at one place.

Microscopically the material consisted of innumerable fibres running in all directions, sometimes singly, but often in groups and bundles. These fibres or bundles

were separated, in some parts, by non-staining homogeneous material which merged in other areas into a blue (hæmatoxylin staining) mucoid substance.

The fibres varied in thickness and in places were segmented and there were numerous ovoid nuclei associated with them. Silver impregnation confirmed the diagnosis of nerve fibres. Neuraxones were present in many, though not all, fibres.

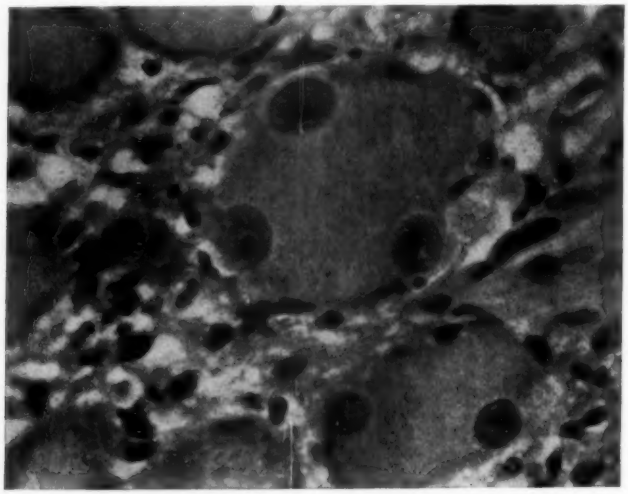

FIGURE V. Photomicrograph showing ganglion cells, one with three nuclei and another with two nuclei in this plane. × 1,700.

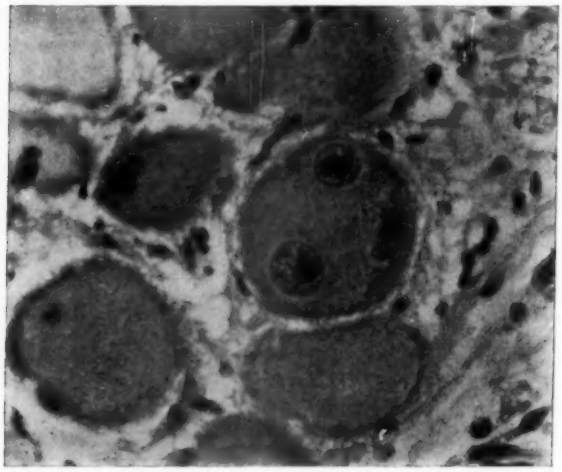

FIGURE VI. Photomicrograph of ganglion cells. These contain many granules in the protoplasm. The nuclei show well developed nucleoli. × 800.

In some areas, corresponding mainly with the yellowish zones observed macroscopically, there were groups of large cells with a hæmatoxylin-staining finely granular protoplasm, a more deeply staining peripheral zone and a large round or ovoid nucleus containing a distinct nucleolus (Figures III and IV). Nissl's granules were demonstrated in these cells. In some places they could be shown to be continuous with nerve fibres (Figure VII). Occasional cells possessed an eosinophilic protoplasm. Some of the cells

contained two or even three nuclei in one section (Figures V and VI). Evidence of mitosis was found in some of these cells. The tumour was thus a typical ganglioneuroma.

Discussion.

This tumour presented a problem for diagnosis which was not solved for a considerable time after the soldier was first seen. The common association of an enlarged spleen with so many tropical diseases obviously influenced various observers, because findings noted on his papers were such as to have made the diagnosis clear, had these been dispassionately considered.

The persistent eosinophilia was a definitely disturbing "red herring". That this was intimately associated with the presence of round worms has been shown by its reduction to 2% after a course of treatment for them.

The attack of giant urticaria was probably associated with the worm infestation and strictly comparable with the condition as usually observed; and although the relationship to removal of the tumour and possible alterations in the adrenal secretion opens up interesting fields for speculation, these cannot profitably be followed here.

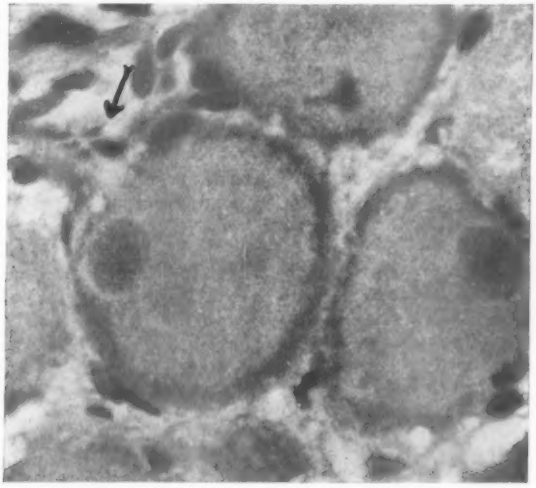

FIGURE VII. Photomicrograph of ganglion cells. The arrow indicates where a cell is continuous with a nerve fibre. × 1,700.

The tumour was not proved to arise in the suprarenal gland as conclusively as it would have been at autopsy, since operative investigation of the very vascular area at the site of the tumour pedicle (after removal of the mass) was not considered justifiable. However, its distance from the aorta and the general position of the hilum in relation to the upper pole of the kidney made this extremely probable.

A very good description of these tumours was given by Dunn and a bibliography of the literature by McFarland. Several cases of removal of ganglioneuroma arising in the sympathetic chain have appeared in the recent literature, but very few examples of the adrenal type have been removed successfully at operation. That described by Forni is a noteworthy example.

Acknowledgements.

The photographs of the macroscopic specimen were prepared by Major J. Devine and the photomicrographs were prepared at the pathology school, University of Melbourne. I am indebted to Professor P. MacCallum for making the facilities available.

Bibliography.

J. S. Dunn: "Neuroblastoma and Ganglioneuroma of the Suprarenal Body", *The Journal of Pathology and Bacteriology*, 1915, Volume xix, page 456.

G. Forni: "*Tumore (ganglioneuroma) retroperitoneale a sede pararenale*", *Giornale Veneto di scienze medica*, January, 1935, Volume ix, page 1.

J. McFarland: "Ganglioneuroma of Retroperitoneal Origin", *Archives of Pathology*, January, 1931, Volume xi, page 118.

Addendum.

Ganglioneuroma of the Lumbar Sympathetic Chain.

Shortly after the foregoing case had been observed, another example of ganglioneuroma appeared in the wards.

C.C., aged thirty-one years, had had no illnesses until May, 1942, when he developed cerebro-spinal meningitis. He recovered from this without incident.

In January, 1943, he developed pain in the left side radiating towards the umbilicus. There was some frequency of micturition associated with this, but no abnormal constituent (other than calcium oxalate crystals) was found in the urine. On examination a mass (firm, extending from the left costal margin to just above Poupart's ligament, not moving on respiration) was found. Various investigations showed displacement of the left kidney upwards without involvement in the mass which was visualized and a normal uninvolved colon. The Wassermann test and hydatid complement fixation test both failed to produce a reaction. Hæmoglobin value was 107%, the leucocytes numbered 9,000 per cubic millimetre, and the differential cell count was normal.

Operation was performed. A left paramedian incision with a lateral right-angled limb at the upper end gave adequate exposure. The colon was freed and turned medially. A mass about 18·0 by 14·0 by 12·0 centimetres was demonstrated to be attached just to the left of the aortic region. After dissection its base measured about 10·0 by 3·0 centimetres and was firmly fixed between the aorta and left psoas muscle. In this region the fixity gave the impression more of its being wedged (with a deep expanded area) rather than of infiltration of tissues. There were large veins on the surface, and these discouraged any attempt to remove the tumour piecemeal. A portion of the tumour was taken for microscopy, bleeding being controlled by deep sutures.

The patient made a satisfactory post-operative recovery.

Pathologically the tumour did not differ in any significant way from the one described above. The external features were similar, the cut surface presented the same soft white "mucoid" appearance and microscopically comparable fields of sections of the two tumours were indistinguishable.

THYMIC HYPERPLASIA AND MYASTHENIA GRAVIS.[1]

By E. S. J. King,
Lieutenant-Colonel, Australian Army Medical Corps.

During the last few years cases of associated abnormalities of the thymus with *myasthenia gravis* have been recorded with increasing frequency. There have been several in which removal of the thymus has been followed by clinical improvement and indeed recovery.

Many of these have been examples of tumours or gross local hyperplasias of the gland, and most attention has been given to neoplasms. However, it would seem that any anomaly of the thymus associated with increased secretion may be responsible for the general muscular disturbance. This has been noted in the literature, but attention has been directed, perhaps not unnaturally, to the more obvious morphological abnormalities.

The following case is one in which there was hyperplasia without gross enlargement of the organ and without any definite mass of tissue justifying the term "tumour".

Clinical History.

M.V.M., aged twenty-seven years, went through the campaigns of Libya, Greece and Crete without incident from the medical point of view. In June, 1941, he developed sandfly fever and immediately after this noticed that he was weaker than usual; but this cleared up rapidly and completely. From July to October he was treated for multiple skin infections, apparently streptococcal, and at the end of this period he noticed that he became tired after walking 400 to 500 yards and he had to sit down and rest. During this period he had an attack of "dysentery", but the nature of this was not proved bacteriologically. In November he contracted gonorrhœa, for which he was treated, and a month after this a blood Wassermann test produced negative results.

He returned to duty, and this was carried out without complaint except for (*a*) several attacks of tonsillitis and (*b*) weakness of and pain in his feet, which was treated as "metatarsalgia".

In May, 1942, his tonsils were removed under local anæsthesia, and it was noticed that his voice was thick and that there was a definite paresis of the right side of the palate. He complained of generalized weakness and stated that he had lost three stone in weight in three months. General nervous examination revealed no abnormality, and frequent attempts to produce cultures of Klebs-Loeffler bacilli failed. In the middle of June he was admitted to hospital with progressive fading of the voice after talking and some difficulty in swallowing, particularly of solids. The vocal cords were crescentic; ptosis of the eyelids was noted and general weakness of all muscles was observed and found to become increased after walking. There was enlargement of several groups of lymph glands.

Injections of prostigmine were given and it was found that 2·0 milligrammes produced a definite improvement in muscle contraction and absence of fatigue in fifteen minutes, reaching a maximum in forty minutes and lasting for an hour and a half. The Kline test now gave a positive reaction.

He was repatriated and arrived at a base hospital on July 30, 1942. He now gave a history of weakness of the limbs (in fact "every muscle"). He also stated that he had a feeling of "numbness" or "fogginess" in the head. He was comfortable when lying down, but the weakness appeared to increase when he used muscles. On examination there was drooping of both eyelids, definite weakness of the voice and wasting of limb muscles. There was weakness of closure of the eyes, poor pharyngeal and palatal reflexes and weakness and trembliness of the muscles. Deep reflexes were active.

Special investigations were as follows. The blood gave a strongly positive reaction to the Wassermann test, but the cerebro-spinal fluid gave no reaction. The blood sodium content was 345 milligrammes per 100 cubic centimetres of serum. The blood potassium content was 19 milligrammes per 100 cubic centimetres of serum. X-ray examination of the chest showed no abnormality and no evidence of any mass in the upper mediastinum.

Operation was considered, but it was decided that he should have anti-specific treatment first and a course of "Novarsenobenzol" was given. During this period his muscle condition remained stationary.

[1] Accepted for publication on March 9, 1943.

On October 20 operation was carried out. This was performed under local anæsthesia. With the patient lying on his face, local block anæsthesia of nerve roots from the eighth cervical to the third dorsal was produced (0·5% "Novocain" being employed). He was then turned and a barrage of local anæsthetic solution was injected across the neck just above the clavicles to block the superficial branches of the cervical plexus.

An I-shaped incision was made, the vertical limb extending from the suprasternal notch in the mid-line to the region of the third rib. Flaps were dissected back, the sternum was exposed and this was cut in the mid-line with Schumacher's sternum shears. The second interspace on each side was opened and a director passed under the sternum. A Gigli saw was then passed and the sternum was cut across by this means. This was done very easily. The two halves of the sternum were then retracted laterally. A small amount of fat was found and deep to this a layer of fascia through which could be seen an elongate solid structure. The fascia was incised and the greyish-yellow thymus was dissected from the surrounding tissues. This extended from the level of the cricoid cartilage to below the level of the third rib. Dissection was easy, vessels running to it being small; these were clamped before division. The lower poles of the thyreoid gland appeared normal. The parathyreoid bodies were not seen. Hæmostasis being effected, the wound was closed. A drainage tube was inserted into the upper mediastinum.

FIGURE I. Photograph of thymus removed at operation.

The patient had been observed carefully for any alteration in, or embarrassment of, respiration during the procedure, but there was never at any time cause for anxiety.

Convalescence was uneventful, though there was some transient respiratory difficulty on the second day. Drainage from the tube, which had been connected to a negative pressure apparatus, was 150 cubic centimetres in two days, after which the tube was removed. The wound healed without incident.

Pathological Examination.

The specimen was an elongated structure consisting of one long left lobe and a small right lobe. It was 13·75 centimetres in length. At the lower end it measured 2·5 by 1·25 centimetres, in its middle part 1·2 by 1·25 centimetres, and at the upper end 0·5 centimetre in diameter. The weight of the organ was 10 grammes. There was a prominent nodule in the upper portion of the left lobe (see Figure I).

Microscopically there was a relatively larger amount of thymic tissue, in proportion to the fat, than normal (Figure II). There was predominance of an "endothelial" type of cell and relatively few small round cells. The spindle and polyhedral cells were prominent even in the cortical zone. Some of the polyhedral or spheroidal cells possessed definite eosinophilic protoplasm (Figure VII). There were more Hassall's corpuscles than usual. These were in all stages of development and most prominent in the areas where the spindle and polyhedral cells were numerous. A number of the polyhedral cells showed definite and clear mitotic figures (Figures VIII and IX).

Subsequent Course.

In the three weeks following operation a remarkable improvement was observed. The patient's voice became stronger and his ocular ptosis gradually disappeared.

An attempt was made to follow his general muscular state by an actual measurement of improvement. This was done by noting the number of times that he was able to put out his tongue. This was done several times a day and the average was taken. As far as possible this was done at the same times and with the same relationship to

meals and other activities. The end-point at which complete inability to protrude the tongue occurred was quite sharp.

Before operation this was found to be from five to eight times. No observations were made for three days after operation, but following this the improvement was considerable, progressive and definite. This is shown in the graph (Figure V).

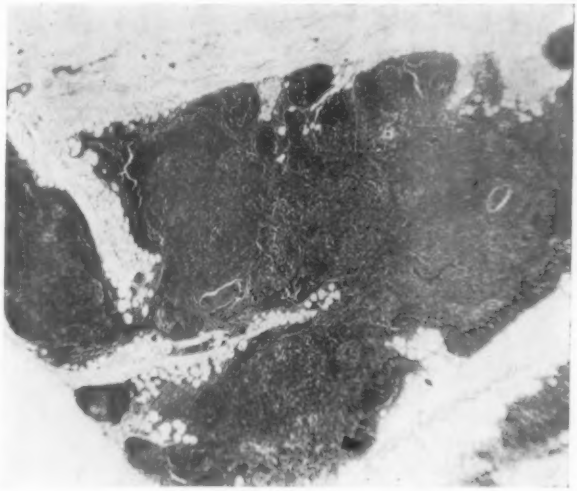

FIGURE II. Photomicrograph (low power) showing portion of thymus. It resembles normal thymus closely, but there is much less "cortex" than usual. × 35.

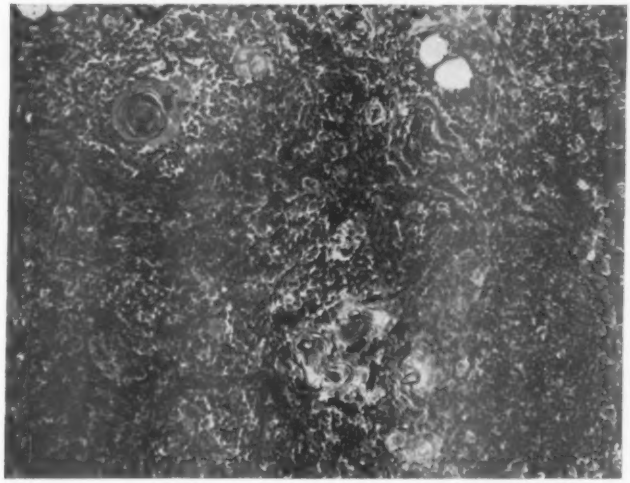

FIGURE III. Photomicrograph of portion of the gland showing its general structure. There are numerous large cells amongst the small round cells (thymocytes) and several Hassall's corpuscles. × 120.

After a fortnight he was able to walk about easily and with less fatigue than before operation. This improvement also continued.

Two features that he volunteered are worthy of note. He noticed that "there was less saliva" after operation than before, because his pillow, which used to be moist

before operation, was now not so. The inference is obvious—it was an improvement in the muscles of deglutition, but the patient did not appreciate this. The other was that the nursing staff noticed, what the patient also stated, that attacks of mild nocturnal dyspnœa, enough to wake him at night, disappeared.

He stated that his most satisfying improvement was that the "numbness" of the head, "cloudiness" and "inability to think clearly" had disappeared. This might have some bearing on the muscular hypothesis of thought or, on the other hand, be associated with some side action of thymic secretion.

After one week an injection of prostigmine was associated with slightly increased peristalsis of the gut—an observation not previously made. At the end of a fortnight, however, a similar injection of two milligrammes was followed by extreme colic and desire to defæcate.

Three weeks after operation he was sufficiently well to be able to take leave that was due to him.

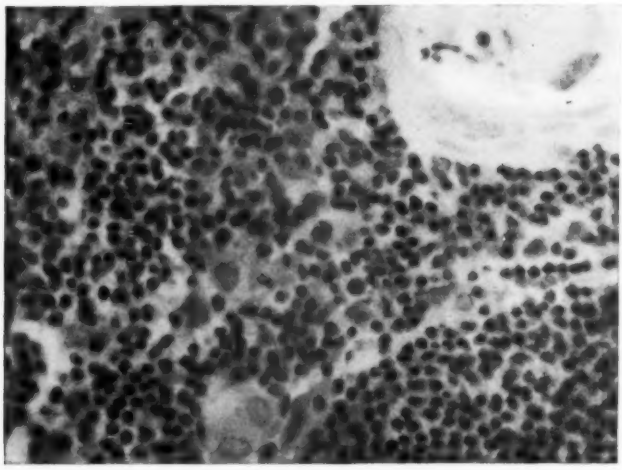

FIGURE IV. Photomicrograph showing large spheroidal cells amongst the small round cells. Portion of a Hassall's corpuscle is to be seen. × 400.

Five weeks later (two months after operation) he returned to hospital. He was feeling quite well. He was now able to protrude his tongue an indefinite number of times without fatigue (the examiner becoming fatigued before the patient). He was able to walk long distances. He noticed some fatigue after strenuous exercise, for example, "after chopping wood".

His wound was soundly healed and there were no symptoms related to the upper part of the chest. No abnormalities were found on general examination. The Wassermann test yielded no reaction. Arrangements were made for a further course of anti-specific treatment and he was returned to light duty.

Discussion.

The association of disease of the thymus gland with *myasthenia gravis* was recorded first by Weigert in 1901. The relationship, however, was not at all clear. The lymphorrhages that occur in the muscles were regarded as possible metastases from a thymic neoplasm. The occurrence of lymphorrhages in muscles in a number of muscle diseases had been noted, however, and the thymic condition in *myasthenia gravis* was regarded as not being neoplastic by the English neurologists (Buzzard).

Gradually further cases were observed in which an abnormal thymus was associated with myasthenia, and a "tumour" of the thymus was noted in this relationship by Hart in 1915.

The recorded cases were reviewed by Bell in 1917 and again by Norris in 1936. Further cases were added in 1939 by Blalock *et alii*, and in 1942 Poer discussed additional cases, and at this time, among 129 cases investigated, definite thymic peculiarities (enlargement, persistence or tumour) were found in 71. Poer pointed out that the proportion of cases in which a definite abnormality of the thymus was

discovered, had increased considerably in recent years, thus supporting the contention of Norris that the more carefully examination is performed, the more frequent will such association prove to be.

This gradual demonstration, by series of cases, of a relationship is well shown in the literature, and reference should be made to the papers of Bell, Norris, Miller, Blalock *et alii* (1941) and Poer.

Surgical attack on *myasthenia gravis* by removal of the thymus began in 1912. Several surgeons operated on patients (Sauerbruch, Haberer and later Leriche) with but indifferent success. The failures were due principally to a concomitant thyreotoxicosis or mediastinal infection. In recent years, however, successful cases have been recorded by Blalock (Blalock *et alii*). The results have been so satisfactory that they justify further attempts at this method of alleviating the condition. A malignant tumour was removed by Poer with relief of the systemic phenomena.

In passing it may be noted that deep X-ray therapy has not been so satisfactory as operative treatment. Death immediately after irradiation has occurred (Aronson) and Poer observed a severe reaction after the application (on one occasion) of this method of treatment. Other cases are described in the literature.

Experimental work carried out shows that there is a physiological relationship between the thymus and muscle weakness. Injections of thymus extract produce definite muscle weakness; such is found also when transplants have grown and developed

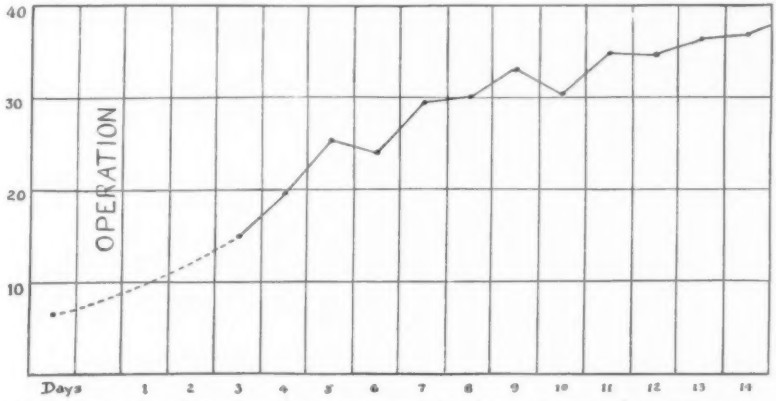

FIGURE V. Graph showing the improvement in ability to protrude tongue after operation. The average number of times of tongue protrusion (observations being made under similar conditions) is given before, and from third to fourteenth day after, operation (see text).

(Adler, 1937). In addition the muscle fatigue present after extirpation of the adrenals which responds to the administration of adrenaline, is also less after removal of the thymus (Adler, 1939). Other observations will be found in the literature.

It is clear therefore that the clinical observations, the therapeutic results of operation and the experimental findings demonstrate quite adequately that there is a relationship between the thymus and *myasthenia gravis*. A reasonable hypothesis is that the thymus produces a chemical substance which has some inhibitory action on muscle excitation at the neuro-muscular junction.

Various types of conditions have been observed in the thymus in *myasthenia gravis*. There has been "persistence" of the gland, hyperplasia, local overgrowth ("adenomata"), definite benign tumours and rarely malignant disease (Meister, Symmers, Poer). From statements in the literature it would seem to have been a matter for some astonishment that tumours are not always present and that the relatively common malignant tumours are not found in *myasthenia gravis* more frequently.

If the muscle changes are due to cellular activity and secretion, a relationship similar to that observed, say, between the thyreoid gland and thyreotoxicosis might be expected. Thus a normal sized gland (microscopically showing hyperplasia) would be as important as, or more important than, a true neoplasm. One should expect that malignant tumours (in which the cells are proliferating and not usually differentiated to the adult or physiologically active, secreting form) would not often show the

functional relationship, and this indeed is usually the case. Incidentally many of the "tumours" described in the literature are probably but local hyperplasias.

Thus a neoplasm of the thymus should not be expected as an associated lesion in *myasthenia gravis*. An "adenoma" which, like many of those in the thyreoid, is merely a localized hyperplasia (but nevertheless a morphologically obtrusive lesion) may be

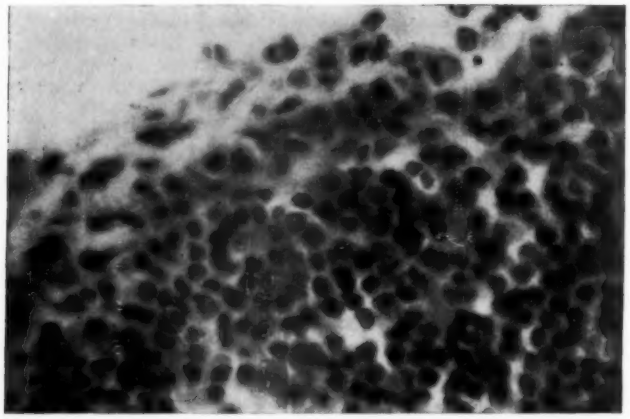

FIGURE VI. Photomicrograph showing margin of a lobule of thymus. Note that the cells are of polyhedral type and not predominantly thymocytes as in the normal lobule. This condition is observed in a fœtal gland and in growing transplants. × 800.

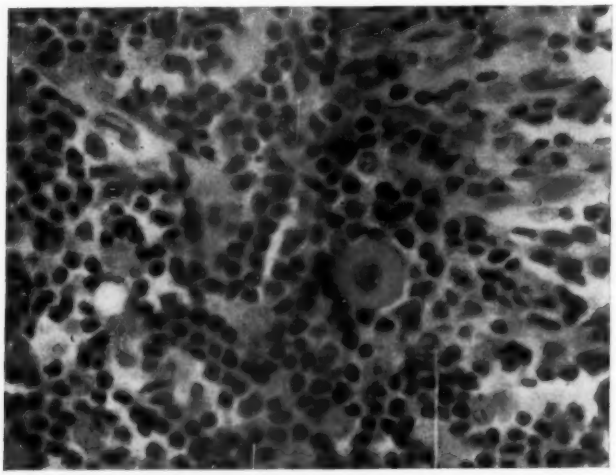

FIGURE VII. Photomicrograph showing a typical large spheroidal cell. × 800.

and has been found relatively frequently. A simple hyperplasia without gross macroscopic change, as in the case described here, can produce the characteristic systemic disturbances; and this may be an explanation for the absence of an account of a thymic abnormality in many of the cases of the disease described. It is clear that pathological changes in the thymus require careful study in all cases so that confusion in terminology (which is similar to that prevailing with other ductless glands) may be clarified.

This problem has been emphasized because, though it has been discussed in the literature (Norris), insufficient attention has been paid to it. As stated, most attention has been directed to the morphologically striking lesions.

The transmission of the excitory impulse across the neuro-muscular junction is regarded as being of a chemical nature—the local liberation of acetylcholine. The chemical hypothesis was first suggested by Elliott in 1904. This received support from Dale (1913), and the evidence for the view has been reviewed by Eccles.

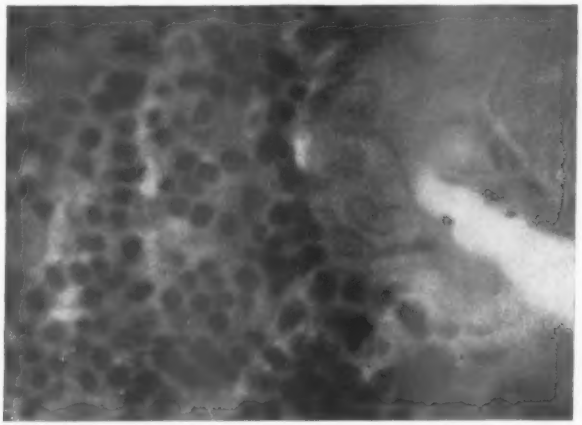

FIGURE VIII. Photomicrograph showing a cell, which contains a mitotic figure, near a Hassall's corpuscle. × 800.

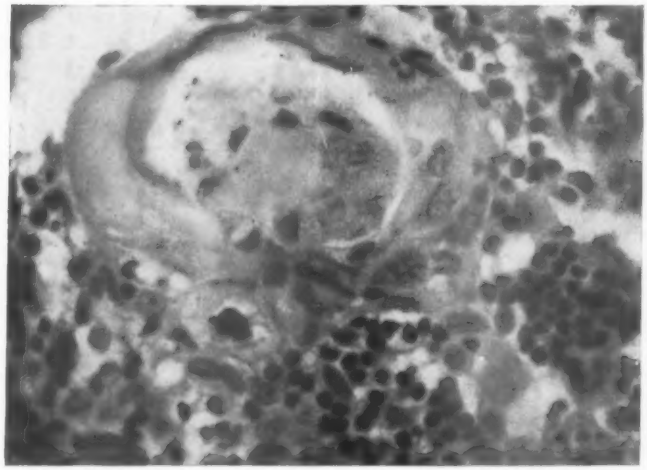

FIGURE IX. Photomicrograph showing a cell with a mitotic figure adjacent to a Hassall's corpuscle. × 800.

The present hypothesis is that acetylcholine is liberated at the nerve ending, but is rapidly destroyed by a cholinesterase.

The local peculiarity in *myasthenia gravis* is unknown. There are three possibilities: (i) That the precursor of acetylcholine is altered so that inadequate acetylcholine is formed. (ii) There is an excess of the esterase. (iii) There is inhibition or damping down of the muscle response independently of the other two factors as occurs in curare poisoning.

It would seem that the third of these is the most likely, but just what bearing the thymus enlargement or hyperplasia (and the increased secretion) has, is as yet a mystery.

There are certain pharmacological phenomena which have an important bearing on myasthenic conditions, especially from the point of view of treatment.

Some drugs temporarily improve muscle contraction. Such are benzedrine, ephedrine, glycine, guanidine and physostigmine. For the most part they act by increasing the nervous stimulus, facilitating its passing to the muscle or increasing the ability of the muscle to respond. Physostigmine, which acts at the end plate by inhibiting the action of the esterase, is the most effective.

Other drugs inhibit transmission of impulses at the end-plate. These are quinine salts, local anæsthetics of the "Novocain" group and the barbiturates.

The effect of quinine on the patient described here was demonstrated during his convalescence. Thus, on one occasion, for example, when he was able to protrude his tongue thirty times before complete fatigue, he was able to protrude it only twenty times two hours after he had been given seven and a half grains of quinine sulphate. It seems probable that this also explained the development of transient weakness during an attack of fever three to four months before the definite onset of frank myasthenia.

Local anæsthesia was used for the operation in this case. A minimum quantity of 0·5% "Novocain" was employed, and the patient was watched carefully for respiratory disturbance, but no untoward effect was observed. However, the possible ill-effects of local anæsthetic agents must be carefully considered whenever operation is to be performed in these cases. Barbiturates were avoided in this case both before and after operation.

Despite the economic difficulties imposed by the war, a great deal of attention is being paid to the question of relationship of thymic secretion to neuro-muscular end-plate function. The recent literature contains several contributions to the problem (approached from various aspects) which will be found of value to those interested in the subject. The progress of the last few years definitely foreshadows significant advances in the not too distant future.

Summary.

A case of *myasthenia gravis* in a soldier on active service is described.

A satisfactory recovery followed removal of a slightly enlarged but hyperplastic thymus gland.

The pathological changes occurring in the organ in such cases are discussed.

Acknowledgement.

My thanks are due to Professor P. MacCallum for making available the facilities of the Department of Pathology, University of Melbourne, where the photomicrographs were prepared.

Bibliography.

H. Adler: "*Thymus und Myasthenia*", *Archiv für klinische Chirurgie*, Volume xxxix, 1937, page 529; "*Thymusfunktion und Nebennieren*", *Deutsche Zeitschrift für Chirurgie*, Volume cclii, 1939, page 241.

S. F. Aronson: "Myasthenia Gravis: A Discussion, with Presentation of a Case Associated with a Thymoma", *Annals of Internal Medicine*, July, 1941, Volume xv, page 137.

E. T. Bell: "Tumor of the Thymus in Myasthenia Gravis", *Journal of Nervous and Mental Disease*, Volume xlv, 1917, page 130.

A. Blalock, M. F. Mason, H. J. Morgan and S. S. Riven: "Myasthenia Gravis and Tumors of the Thymic Region: Removal", *Annals of Surgery*, October, 1939, Volume cx, page 544.

A. Blalock, A. M. Harvey, F. R. Ford and J. L. Lilienthal, junior: "The Treatment of Myasthenia Gravis by Removal of the Thymus Gland", *The Journal of the American Medical Association*, Volume cxvii, 1941, page 1529.

E. F. Buzzard: "Case of Muscular Wasting with Unusual Symptoms", *Brain*, Volume xxviii, 1905, page 359.

H. H. Dale: "The Action of Certain Esters and Ethers of Choline and their Relation to Muscarine", *Journal of Pharmacology and Experimental Therapeutics*, Volume vi, 1914, page 147.

J. C. Eccles: "Synaptic and Neuromuscular Transmission", *Physiological Reviews*, October, 1937, Volume xvii, page 538.

T. R. Elliott: "The Action of Adrenalin", *Journal of Physiology*, Volume xxxi, 1904, page 20; Volume xxxii, 1905, page 401.

H. v. Haberer: "*Zur klinischen Bedeutung der Thymusdrüse*", *Archiv für klinische Chirurgie*, Volume cix, 1917, page 193.

C. Hart: "*Bedeutung der Thymus für Enstehung und Verlauf der Morbus Thymusstudien*", *Virchows Archiv für pathologische Anatomie*, Volume ccxx, 1915, page 185.

R. Leriche and A. Jung: "*Thymectomie dans un cas de myasthénie*", *Mémoires de l'Académie de Chirurgie*, Volume lxv, 1939, page 334.

M. Meister: "*Lymphoepitheliales Thymustumor und Myasthenie*", *Klinische Wochenschrift*, September 26, 1936, Volume xv, page 1389.

H. G. Miller: "Myasthenia Gravis and the Thymus Gland", *Archives of Pathology*, February, 1940, Volume xxix, page 212.

E. H. Norris: "The Thymoma and the Thymic Hyperplasia in Myasthenia Gravis, with Observations on the General Pathology", *American Journal of Cancer*, 1936, Volume xxvii, page 421; "A Thymoma (Adenoma of the Thymus) from an Unusual Case of Myasthenia Gravis, with Observations on the General Pathology", *American Journal of Cancer*, 1937, Volume xxx, page 300.

D. H. Poer: "Effect of Removal of Malignant Thymic Tumor in a Case of Myasthenia Gravis", *Annals of Surgery*, April, 1942, Volume cxv, page 586.

E. D. Schumacher and Roth: "*Thymektomie bei einem Fall von Morbus Basdowie mit myasthenie*", *Mitteilungen aus den Grenzgebieten der Medizin und Chirurgie*, Volume xxv, 1912, page 746.

D. Symmers: "Malignant Tumors and Tumor-like Growths of Thymic Region", *Annals of Surgery*, 1932, Volume xcv, page 538.

C. Weigert: *Neurologisches Centralblatt*, Volume xx, 1901, page 597.

HORSESHOE KIDNEY AND HYDRONEPHROSIS.[1]

By Richard Flynn,
Sydney.

F.H.J., a male, aged forty-five years, born in Sweden, and a miner by occupation, sought medical treatment at the Royal Prince Alfred Hospital, Sydney, on account of frequency of micturition and soreness across his back during the preceding two years. He had also noticed burning on micturition. After a day's heavy work he had suffered from a dull pain in both loins, but he had had no colic and he had not noticed blood in his urine. The pain in his back had recently become more severe and more constant. He had lost three stone in weight during the last two years. He had noticed dizziness and slight headache, but no drowsiness or blurring of vision.

On examination his systolic blood pressure was 130 millimetres of mercury and his diastolic pressure was 80 millimetres. General physical examination disclosed no abnormality.

A Wassermann test of his blood and a gonococcal fixation test both failed to produce a reaction. A blood urea estimation was made on May 16, 1939, and revealed 66 milligrammes *per centum*; the blood creatinine content was one milligramme *per centum*. His urea concentration was satisfactory and the specific gravity of the urine was 1020.

An excretion urogram on January 16, 1939, was reported on as follows: "There is well marked ptosis of the right kidney and also some rotation. There is marked disorganization of the left kidney and I think a retrograde pyelogram should be done on this side; the appearance is rather suggestive of neoplasm."

On May 10, 1939, under low spinal anæsthesia, cystoscopic examination was carried out. His bladder and ureteric orifices appeared normal and ureteric catheters were easily passed to the pelvis of both kidneys. Ten cubic centimetres of 1% indigo-carmine solution were injected intravenously; the blue from the right kidney was quite satisfactory, but scarcely any blue was secreted from the left side. (This was also the finding at cystoscopic examination at another hospital.) A retrograde pyelogram of the left side was reported on as follows: "Some ptosis of the right kidney; the left kidney is apparently disorganized with very gross hydronephrosis. I cannot see any cause for this, possibly old pyonephrosis" (Figure I).

On May 15, 1939, cystoscopic examination was again done and two large ureteric catheters were passed up into the left renal pelvis and they were not withdrawn, the idea being to decompress the renal pelvis. On May 17, 1939, an intravenous injection of indigo-carmine was repeated and there was good concentration of blue from the catheters. This proved that the functional value of the left kidney was quite good, the poor result on the first occasion being explained by dilution of a normally concentrated blue by the large amount of urine retained in the kidney pelvis.

A pre-operative diagnosis was made of horseshoe kidney with large extrarenal hydronephrosis on the left side, possibly caused by an aberrant vessel. At operation on May 22, 1939, through the usual lumbar approach, the left kidney was exposed, and when isolated it was seen to be joined to the right kidney by an isthmus. This was divided between a series of hæmostatic sutures. When the left kidney was delivered it was seen that it was a cake kidney with its pelvis pointing anteriorly and dilated into a huge extrarenal hydronephrosis, its chief blood supply descending from the aorta and entering it at the upper pole. There was a small vessel arising from the aorta and entering the lower pole; this interfered with the delivering of the kidney into the wound. It was temporarily obliterated, and as no great area of the cortex became engorged it was divided and ligated. A fibrous band crossed in the angle between the pelvis and the ureter, and as it seemed to be the chief cause of the obstruction to the free emptying of the pelvis it also was divided. A Walters plastic operation was done on the kidney pelvis and this was followed by a Cabot nephropexy. The wound was closed in the usual way. The patient developed a post-operative pneumonia which responded well to treatment with "M & B 693".

On May 26, 1939, an intravenous injection of indigo-carmine was given and a perfect blue was obtained from the left kidney through the de Pezzer catheter. The de Pezzer and ureteric catheters were removed on June 10, 1939.

The pathological report on the piece of pelvis resected during the plastic operation on the pelvis was reported on as follows by Dr. Davies: "Section of the pelvis of the kidney shows some loss of superficial epithelium. There is thickening of the wall of the pelvis with small round cell infiltration under the epithelium and accumulations of small round cells in the muscular tissue. Chronic pyelitis."

[1] Accepted for publication on February 18, 1943.

The patient returned for check-up on July 12, 1939. Cystoscopy was performed and both ureters were catheterized. After injection of 10 cubic centimetres of 1% indigo-carmine solution a perfect blue was secreted from both sides. Bilateral retrograde pyelograms were made (Figure II), and a further radiograph was taken ten minutes later to test the emptying time. It is interesting that the side operated on (left) emptied normally, while the emptying time of the right kidney was definitely delayed

FIGURE I.

FIGURE II.

FIGURE III.

FIGURE IV.

(Figure III). An excretion urogram was done on July 13, 1939 (Figure IV). The radiographer reported as follows: "Both kidneys appear to be functioning quite normally. There does not appear to be any apparent dilatation of either renal pelvis." It contrasts markedly with that done on January 16, 1939. The patient states that he has greatly improved in health and that he has been completely relieved of his pain. I have advised him to have a plastic operation done on his right side on account of the high insertion of the ureter into the pelvis on that side, but though grateful for the relief given, he is going to wait and see.

Surgery in Other Countries.

[In this column will be published short résumés of articles likely to be of practical value from Journals published in other countries and not readily accessible to surgeons in Australia and New Zealand.]

WAR INJURY OF THE EYE IN GERMANY.

W. Rohrschneider: "*Die Wirkung neuzeitlicher Waffen bei den Kriegverletzungen der Augen*", *Der Deutsche Militärarzt*, July, 1942, Number 7, page 417.

Karl Mylius: "*Schwere Augenverletzungen: Erste Hilfe und endgultige Versorgung*", *Der Deutsche Militärarzt*, July, 1942, Number 7, page 423.

THE communications of these two German surgeons reveal an enormous increase in the incidence of war injuries of the eye on the Russian front. There were, they state, many reasons for this. Among these they include the following: the greater use of explosive action in all modern weapons; the much greater employment of mines by the Russians; the increased use of metal protective appliances; the fact that Russian steel breaks into small fragments; the increased use of hand grenades, aeroplane bombs and high explosive shells; and finally wood splinters from fighting in the forests, which was a feature on the Russian front. The enormous number of fine metal splinters was a fertile cause of these eye injuries. Of the eye injuries 21% were caused by mines. Originating from the explosion, metal particles, grains of sand, dirt, bits of stone, even at some distance from the mine, were driven into the cornea and the conjunctiva, generally of both eyes. On the character and number of these foreign particles, on the depth to which they had penetrated, on their potentiality to cause corneal ulceration and on the degree of bilateral involvement depended the seriousness of this kind of eye injury. Corneal ulceration following mine injuries was a not infrequent cause of loss of sight in both eyes. Sometimes these small foreign bodies in the eyes healed in position without causing secondary ulceration. And in this case there was little deterioration of vision.

Eye injuries were also caused in another way—by bullets striking protective apparatus. A bullet meeting the resistance of a steel helmet, the shield of a machine-gun or the edge of the *Sehschlit* (the outlook slot) of a tank caused the lead suddenly to melt and burst the jacket of the bullet with a perceptible explosion. From the burst came with great force a cloud of fine lead dust which, impinging on the eyes, infiltrated them with a host of these fine lead particles—it effected what was practically a lead infiltration (*Bleispritzverletzungen*).

These lead particles sometimes penetrated into the anterior chamber and the lens and often into the vitreous humour. In some cases so small were they that only X-ray examination could detect them. They were usually well tolerated and in most cases the prognosis in regard to vision was favourable.

Many serious eye injuries occurred in cases of facial gunshot wounds in which no direct damage to the eye could be detected. In these cases vitreous effusions and greyish-white regions in the eye backgrounds were seen.

In the very severe eye injuries, where the eyeball had been opened, Mylius found that the fate of the eye or eyes was often decided by the efficiency of the first-aid care. The first aid was: to make no attempt to find the extent of the injury; to place the injured eye at complete rest by bandaging both eyes and giving the patient an intravenous injection of "Scopolamin-Eukodal-Ephetonin" (Merck), which kept him free from pain and obliterated any spasmodic eye movement.

Patients with these severe eye injuries were quickly relayed to a hospital specially equipped to deal with eye injuries. No operation in forward hospitals was allowed; operations by non-specialists in forward areas were the cause of loss of many eyes. The wounds of the eyeball were sutured in layers, in some of which sterilized women's hair was used. A good deal of success attended the prompt repair in a special department for these very severe eye injuries.

H. B. DEVINE.

Reviews.

Medical Ethics. By RUPERT M. DOWNES, C.M.G., V.D., M.S., F.R.A.C.S.; 1942. Melbourne: W. Ramsay (Surgical) Proprietary, Limited. 8½" × 5½", pp. 78. Price: 5s.

MAJOR-GENERAL DOWNES has used the late Dr. Anderson's Melbourne University lectures on medical ethics as a basis and incorporated much of the original material.

The author's purpose is to meet the needs of the young medical man entering "upon practice with no clear knowledge as to the ethical relation in which he stands to the State, to the public, to his patients and to his fellow practitioners". He is thus, as Major-General Downes states, "apt to find himself involved in misunderstandings with various sections of the community and in initial difficulties much more numerous and trying than they need be". The book "makes no pretence to any philosophical or exhaustive consideration of medical ethics. It aims at being merely a plain statement of the present understanding of its principles, especially as they apply to the Victorian medical practitioner."

Adopting a broad definition of medical ethics as the moral obligations of a medical practitioner in the practice of his profession, the author proceeds to explain, with helpful comment throughout, the rules of conduct for its members toward their fellow members and patients laid down by the governing body of the medical profession. Further, his subject, in his conception, includes the practitioner's obligations to the State. He recognizes that it is thus apt to overlap the confines of forensic medicine. For practical purposes it must, he says, also include the etiquette involved in relations with fellow practitioners, a breach of which is one of manners or good taste rather than of moral principles. Many of the problems of this nature that are likely to arise are described, and much valuable guidance of a practical nature is given. As the reference throughout is to Victorian conditions and the ethical decisions of the local branch of the British Medical Association, the usefulness of the book is practically confined to the limits of that State.

Usefully included as appendices are the ethical principles of the British Medical Association (Victorian Branch) and the rules of the Parent Body in respect of consultations and supersession, as well as the explanatory notice to medical practitioners concerning the *Medical Act* of Victoria, issued by the Medical Board of Victoria.

The Hemorrhagic Diseases and the Physiology of Hemostasis. By ARMAND J. QUICK, Ph.D., M.D.; 1942. Springfield, Illinois: Charles C. Thomas. London: Baillière, Tindall and Cox. 6″ × 9½″, pp. 357, with 24 illustrations. Price: $5.00.

CLINICIANS will particularly associate the name of the author with the now standard routine test for the estimation of prothrombinæmia in patients suffering from one of the hæmorrhagic diatheses, on whom a surgical operation may be necessary.

The problems of hypothrombinæmia, thrombocytopenic *purpura hæmorrhagica* and the hæmorrhagic diathesis of avitaminosis *K* have been the subject of considerable physiological and pathological research during the past decade, and some very conflicting views have been expressed. This excellent monograph by Armand J. Quick, which is based on a series of lectures given under the auspices of the Beaumont Lectureship Foundation, clarifies the whole subject.

The first chapters deal with the various theories and experiments on which present-day views of hæmostasis are based, and the latter half of the book consists of descriptions of the different hæmorrhagic diseases. Researches on which the underlying pathological conceptions are based, are analysed in a clear, concise and unbiased manner. A very complete classification of these diseases is given in the last chapter, and the book concludes with an appendix on clinical methods for the investigation and study of hæmorrhagic diseases.

We would particularly commend the excellent bibliography appended to each chapter. The author is to be congratulated on the production of a book of such authority on a subject whose pathology has always been complicated, that it will certainly become a standard work of reference.

Plastic Surgery of the Breast and Abdominal Wall. By MAX THOREK, M.D.; 1942. Springfield, Illinois: Charles C. Thomas. London: Baillière, Tindall and Cox. 6⅝″ × 9⅞″, pp. 459, with illustrations. Price: $16.50.

THE main feature of Max Thorek's book is a comprehensive and beautifully illustrated monograph on the plastic surgery of the breast; only fifty pages are devoted to the plastic surgery of the abdominal wall.

The *raison d'être* of the work, Max Thorek writes, is the need to put this little practised branch of plastic surgery of the breast on a sound basis. He points out that in the "Gibson Girl" days, when woman was fighting for a place in the business world, she sought to tone down her sex characteristics. But today, when this battle is won, she desires to accentuate her sex. Magazines, fiction, advertisements, the stage and the screen give glamour to those human factors which go to make up what is called sex appeal; and of these the female breast is by far the most tangible and the most accentuated. Perfection of form of the breast in the modern female is thus an æsthetic requirement of the woman of today. To relegate the plastic surgery of the female breast

to the charlatan and unskilled because of the aura which has surrounded it in the past is to evade a professional responsibility.

An idea of the matter contained in the monograph on the breast may be obtained from a knowledge of some of the aspects dealt with by the author. There are chapters on the anatomy, histology, embryology, histophysiology and physiology of the breast; on comparative anatomy; on the development and character of the breast; on its racial characteristics and folk lore relating to it in the centuries past; on congenital anomalies; on hypertrophy of the female breast; and on gynæcomastia and amastia.

Full consideration is given to the indications for reconstructive surgery of the female breast. The author has collected all the important literature on this subject during the last twenty-five years, has set it out simply and concisely, and has illustrated it profusely. Thus he describes and pictures most plastic operations that have been employed to remedy hypertrophy and pendulosity of the female breast. And to this compendium he has added his own experience on the subject over almost the same period, giving a description of his original operation for the plastic reconstruction of the female breast and a record of the after-results.

The main feature of Thorek's operation is a free transplantation of the nipple and its areola, after which the plastic reconstruction of the breast is comparatively simple. Thorek shows by photographs of patients taken years afterwards that the results of this free transplantation are satisfactory.

Reconstructive surgery in hyperadiposity takes up the greater part of that section of the book which deals with plastic surgery of the abdominal wall.

A feature of the book is the excellent illustrations, many of which are art photographs from Max Thorek's own master hand.

The book is a credit to the publishers and is a needed and a valuable contribution to surgical literature.

Fractures and Fracture Treatment in Practice. By KURT COLESH, M.D.; 1942. Johannesburg: Witwatersrand University Press. 8½" × 5½", pp. 147, with 157 illustrations. Price: 12s. 6d.

THIS little book of 147 pages with 157 black and white line diagrams is intended as a concise summary of that knowledge of fractures which is necessary for the student in order to pass his qualifying examination. As stated by the author in the preface, the work is intended for the purpose of rapid revision of the subject.

Though limited in its sphere, this book has much to recommend it. Clear and dogmatic information of the symptoms and signs of a fracture in general, of the pathology of fracture repair, together with general considerations in fracture treatment, makes up the first part of the book. In the section on fractures of particular bones, clear diagrams show the mechanism of displacement caused by muscle pull of the fractured fragments. In the discussion of fractures in the region of the hip joint there are excellent diagrams showing the various deformities, which should be very helpful to students. A modified Hamilton Russell extension is described.

From the point of view of the student, this book can be thoroughly recommended. But, in its brevity lies its limitations, for there is no room for detail, and even fractures of the face and jaws have had to be compressed into a page and a half.

Renal Lithiasis. By CHARLES C. HIGGINS, M.D.; 1943. Springfield, Illinois: Charles C. Thomas; London: Baillière, Tindall and Cox. 7½" × 4½", pp. 152, with 18 illustrations. Price: $3.00.

IN a small volume is presented the material of the Beaumont Lectures of 1942 given by the author and representing his ten years of study on the ætiology and on treatment of renal lithiasis as conducted at the Cleveland Clinic, Cleveland. The researches undertaken have been mainly from the point of view of vitamin deficiency as an ætiological factor in the causation of stone and the relationship of urinary pH to the deposition of crystals in the urine. Dietary deficiency in vitamin *A* in animals (rats, chickens and dogs) resulted in a high incidence of calculus production, and the feeding of such vitamin-starved animals with high vitamin *A* diet has resulted experimentally in the dissolution of stone.

The use of the biophotometer test of vitamin *A* deficiency proved 68% of patients with calculus disease to be deficient in that vitamin. It was also found that vitamin *A* deficiency in various degrees is more prevalent in presumably normal persons on normal diet than would be expected. The various other factors bearing a possible ætiological relationship to stone formation are discussed. They include infection and the relation of the urea-splitting organisms, hyperparathyreoidism, obstruction and the metabolic conditions, namely, gout, cystinuria, oxaluria, xanthinuria and phosphaturia. The work of Caulk and Randall on the subepithelial calcium plaque in the papillary region of the kidney is lightly touched upon.

A chapter of interest to biochemists refers to the modern complete methods of chemical analysis of calculi. The author points out that a knowledge of the chemical constituents of stone is of paramount importance in the prevention of recurrence.

Various surgical procedures are described for the surgical treatment of renal calculus. Indications for the dietary treatment of renal lithiasis are elaborated. The diet required is determined by an analysis of any stone passed or recovered by surgery, by an estimation of the pH value of the urine or by an examination of the crystals and sediment in the urine. The pH value of the urine is shifted to the acid or alkaline side by the use of the acid ash or alkaline ash diet.

A comprehensive list of foods with their ash content and suggested menus for the attainment of this end complete an interesting compendium of modern knowledge on this important subject.

Illustrations of Regional Anatomy. By E. B. JAMIESON, M.D.; published in seven sections; Sections I to V, Fourth Edition; Sections VI and VII, Third Edition; 1942. Edinburgh: E. and S. Livingstone. 8″ × 6¼″. Price: 60s.

THE welcome accorded earlier editions of Dr. Jamieson's "Illustrations of Regional Anatomy" can be confidently extended to the fourth edition of Sections I to V and to the third edition of Sections VI and VII. These latest editions represent a distinct improvement on the old in that there are 163 new colour blocks in Sections I to V and 79 in Sections VI and VII, whilst certain of the illustrations have been enlarged.

Opinions will always differ concerning the value of anatomical atlases, but it cannot be denied that there are many who derive considerable assistance and benefit from them, provided always that they are used to supplement the practical work in the dissecting room and not to replace it. However, the facilities of the dissecting and post-mortem rooms are not always available for all graduates desirous of revising their knowledge of the subject, while the student making his first contact with anatomy generally finds the pictorial representation of structure a very valuable aid to his practical work. It is to these two groups that anatomical atlases will always have their greatest appeal. Jamieson's illustrations will serve these purposes admirably.

For those not familiar with the earlier editions it should be explained that the publication takes the form of a collection of coloured drawings and schematic diagrams of anatomical structures and dissections. Though the work sets no new standard in the field of anatomical atlases, the illustrations are large, clear, comprehensive, well-labelled and very attractively presented. The relative importance of excluded and included material will always be debatable, but the contents in this particular collection represent a wise selection of the relevant and useful and reflect the author's long and unrivalled experience in the teaching of students. The work has been so carefully and, in general, accurately carried out that there is little to criticize. Certain inaccuracies in these latest editions, however, demand attention. In Section II there are, for instance, no middle superior alveolar arteries as illustrated in Plate 29B, whilst the middle superior dental (alveolar) nerves do not run the course ascribed to them in Plates 11 and 29. In Plate 20 the auriculo-temporal nerve, which supplies only the tragus of the auricle, is shown ramifying widely over the surface of the auricle. The attachments of the urogenital diaphragm shown in Plates 25 and 27 in the section devoted to the pelvis are incorrect. In the section on the upper extremity the attachment of the *extensor* and *flexor carpi ulnaris* aponeurosis to the posterior subcutaneous border of the ulna is omitted, whilst the relationship of the *tendo calcaneus* and its associated bursa to the dorsal surface of the *os calcis* as shown in Plate 29 of Section VII could be improved. Others could be mentioned, but they are not of sufficient significance to detract from the general usefulness of the book. The collection can be confidently recommended to those making their first acquaintance with the subject and to those seeking a rapid ana profitable revision.

Intestinal Obstructions: A Physiological and Clinical Consideration. By OWEN H. WANGENSTEEN, B.A., M.D., Ph.D.; Second Edition; 1942. Springfield, Illinois: Charles C. Thomas; London: Baillière, Tindall and Cox. 10″ × 6½″, pp. 511, with 143 illustrations. Price: $7.00.

THE first edition of this book was reviewed in this journal in July, 1939. The greater proportion of the extra hundred pages in the new edition is devoted to more recent physiological work in connexion with acute intestinal obstruction and the remainder to new operative techniques.

The importance of maintaining the nitrogen balance as well as the fluid and chloride balance is stressed, and details of management are clearly set out in the excellent chapter on post-operative treatment. Loss of secretion if a high fistula is necessary still presents a problem almost impossible of solution. The aseptic type of enterostomy and of anastomosis has been developed and is very clearly described. We

still doubt the assertion, however, that the failure of enterostomy to relieve distension is due to infection following the operative procedure, nor can we agree with the statement that the administration of a spinal anæsthetic results in relief of paralytic ileus.

There is an extensive bibliography at the end of each chapter, the book is profusely illustrated and can be recommended to all who wish to possess a review of the latest physiological work on obstruction of the bowel.

Proceedings of the Royal Australasian College of Surgeons.

ADMISSION OF NEW FELLOWS.

AT a meeting of the Council of the College held in Melbourne on Saturday, October 2, 1943, the following were admitted to Fellowship:

General Surgery.

New South Wales: Stening, Malcolm James Lees.

Victoria: Churches, Clifford Kelvin; Devine, John Berchmans; Rank, Benjamin Keith; Spencer, John Clark.

Laryngo-Otology.

Queensland: Earnshaw, Herbert Gaylard; Quayle, Athol Frederick.

Royal College of Surgeons of England.

REGULATIONS FOR THE FELLOWSHIP.

THE Council of the Royal College of Surgeons of England has revised the regulations for the Fellowship. The primary examination beginning on November 29 next will be the last to be conducted under the present regulations.

The new regulations, which have been approved by the Council and which will become effective as from the end of 1943, embody the following changes:

(i) The primary examination cannot be taken by undergraduates, but will be open only to members of the College or to graduates in medicine and surgery of the universities and medical colleges recognized by the Council for the purpose, who are able to comply with the conditions of the regulations.

(ii) The subjects of the primary examination will be: (*a*) anatomy (including normal histology) and (*b*) applied physiology and the principles of pathology. A synopsis indicating the general scope and spirit of the examination in applied physiology and the principles of pathology is published in the new regulations.

No candidate will be admitted to the final examination without producing evidence of having been engaged in the acquirement of professional knowledge for not less than two years subsequent to the date of having obtained the membership of the College or some other recognized qualification, *vide* (i) above.

The dates of the examinations have been rearranged, so that it will be possible for candidates who pass the primary examination to proceed immediately to the final examination, if they are eligible. During 1944 the examinations will begin on the following dates: primary examination, April 24 and October 23; final examination, May 4 and November 2.

JACKSONIAN PRIZE.

THE Council of the Royal Australasian College of Surgeons has been advised by the Council of the Royal College of Surgeons of England that the subject chosen for the Jacksonian Prize for the year 1944 is as follows: "The Causation and Treatment of Delayed Union of Fractures of the Long Bones." Full details governing the conditions of the prize will be announced at a later date.

The Australian and New Zealand Journal of Surgery

JANUARY, 1944.

TABLE OF CONTENTS.

[The Whole of the Literary Matter in THE AUSTRALIAN AND NEW ZEALAND JOURNAL OF SURGERY is Copyright.]

ORIGINAL ARTICLES— PAGE

Restoration after Excision for Malignant Disease ..... *H. P. Pickerill* 147

The Significance of Hypothenar Elevation in Movements of Opposition of the Thumb ..... *Sydney Sunderland* 155

Flexion of the Distal Phalanx of the Thumb in Lesions of the Median Nerve ..... *Sydney Sunderland* 157

Voluntary Movements and the Deceptive Action of Muscles in Peripheral Nerve Lesions ..... *Sydney Sunderland* 160

Fractures of Facial Bones ..... *B. K. Rank* 184

CASE REPORTS—

Chondroma of a Meniscus of the Knee Joint ..... *L. W. Cox* 199

Carotid Body Tumour (Perithelioma of the Carotid Body) *K. W. Starr, R. Francis, H. Ham and J. J. Tonge* 200

Shattering Gunshot Wound of the Elbow ..... *John Devine* 208

SURGERY IN OTHER COUNTRIES—

Penetrating Gunshot Wounds of the Heart 210

The Treatment of Gunshot Wounds of the Abdomen 212

REVIEWS—

Pictorial Handbook of Fracture Treatment 212

Pye's Surgical Handicraft: A Manual of Surgical Manipulations, Minor Surgery and Other Matters Connected with the Work of Surgical Dressers, House Surgeons and Practitioners 213

The Australian Army Medical Services in the War of 1914-1918 213

Transurethral Prostatectomy 214

The Medical Annual: A Year Book of Treatment and Practitioner's Index 215

Medical Progress Annual 215

Clinical Roentgenology of the Cardiovascular System 215

The Hospital Care of the Surgical Patient 216